



Introduction to Human Osteology

Roberta Hall
Kenneth Beals
Holm Neumann
Georg Neumann
Gwyn Madden

Introduction to Human Osteology

Roberta Hall

Kenneth Beals

Holm Neumann

Georg Neumann

Gwyn Madden

Revised in 1978, 1984, and 2008



Introduction to Osteology

Physical anthropologists study human biological variation in the past and present. They are not only interested in the physical aspect of the body but also how biology, culture and environment interact to produce variation. Part of this variation is found in the bones and teeth. Since these are the hardest parts of the body, they have the greatest chance of being found in the archaeological record. Thus they form the bulk of direct information about the biological course of human evolution.

Structure and Function of Bone

The shape of the skeleton is a reflection of the functions that it performs. Like the steel girders in a skyscraper, it provides a framework and support for the body. Vital organs (such as the brain) are protected by being enclosed in bone. Movement is accomplished by combination with the muscular and nervous system. The muscles attach to the bones and form a system of levers. As the muscles grow, they influence the shape of the skeleton. Most of the projections, nodules, and ridges that you will see were created by the muscles sculpturing areas for attachment. The skeleton is also responsible for the manufacture of blood cells and for the storage of various minerals so that the body can obtain them even if the diet is temporarily deficient.

Bony tissue is about 50% water and 50% solid matter. Most of the solid material is cartilage which has been hardened by the impregnation of inorganic salts, especially carbonates and lime phosphate. As one ages, the proportion of lime increases so that the bones become more brittle and break more easily.

In a living individual, the appearance of bones is very different from skeletonized remains. They are covered with a white fibrous membrane called the periosteum. Cartilage forms the cover around the joints. Muscle fibers interlace with the periosteal fibers to anchor both together. In a growing individual, the inner layer of the periosteum contains the bone forming cells call osteoblasts. Immediately beneath the periosteum is a dense layer of compact bone. Under it lies the cancellous bone. It is much less dense and has the appearance of a spidery framework to give it maximum strength with minimum

weight. The extreme inside of the bone is the medullary cavity. It is surrounded by the endosteum, which is a condensed layer of marrow.

Microstructure of Bone

Under magnification the most notable features are concentric rings, holes, and spidery black regions. The latter dark areas called lacunae are the homes of the bone cells (osteocytes). The osteocytes are interconnected with blood vessels and nerves. These blood vessels and nerves run through the Haversian canals, which appear as holes in cross section. The light colored concentric rings are called lamellae. These represent the places of mineral deposit.

Anatomical Directions

A number of terms are used when studying and researching the human skeleton. It is important to memorize these terms as they will be necessary in placing remains in the anatomical position, siding, and general observation.

Dorsal	Back side of a human, upper side of an animal
Ventral	Front side of a human, belly side of an animal
Lateral	The sides, right and left
Median	The middle
Peripheral	The part nearest the surface
Proximal	Near the main mass of the body
Distal	Away from the main mass of the body
Medial	Toward the middle
Cephalic	Toward the head
Caudal	Toward the tail
Superior	Toward the head
Inferior	Toward the feet

A few terms are also important to memorize regarding the movement that individual bones/muscles are involved in.

Flexion	Bending of a limb
Extension	Straightening of a limb
Abduction	Pulling a limb away from midline
Adduction	Pulling a limb toward midline
Rotation	Movement of a limb around its own axis

Several anatomical features have specific technical terms that are used to describe them. Familiarize yourself with the list provided below.

Diaphysis	Shaft of a bone
Epiphysis	Ends or extremities of a bone, where growth takes place
Metaphysis	Line of junction between the diaphysis and epiphysis
Tuberosity	A rounded eminence or bulging of the bone
Process	Marked projection, articulating bone projection
Spine	Slender or pointed projection
Tubercle	Small nodule
Linea	A slight ridge of bone
Condyle	An enlargement bearing an articular surface
Foramen	Short perforation
Canal	Long perforation
Aperture	Opening on surface or space within a bone
Meatus	Outlet
Trochanter	A large prominence for attachment of rotator muscles
Sulcus	A groove
Sinus	A cavity in bone lined with mucous membrane
Lip	Margin of a groove, crest or line
Head	A rounded, smooth eminence for articulation
Fossa	A furrow or depression
Ramus	A branch of bone

Symphysis	An almost immovable joint; the line of junction between bones
Suture	Seam, line of union in an immovable articulation
Crest	Prominent ridge

The Skull

Handling a Skull

The skulls that you handle while learning osteology were once living humans like yourself, therefore they are deserving of your respect. Handle each skull with great care, using both hands to pick it up. Always place the skull on a bean bag or other padding when putting it down. Do not place your fingers into the eye orbits, nasal cavity, or foramen magnum as these are fragile areas and bone is easily broken. If a cranium has an attached mandible, be extremely gentle when opening and closing the jaw to prevent breakage of the teeth. Be very careful with your pens and pencils; as the skulls used in class will be used by others and it is necessary to keep them as pristine as possible. When taking measurements, very gently place the calipers on the skull; when held too tight on the skull the calipers can scratch the bone.

General Terminology

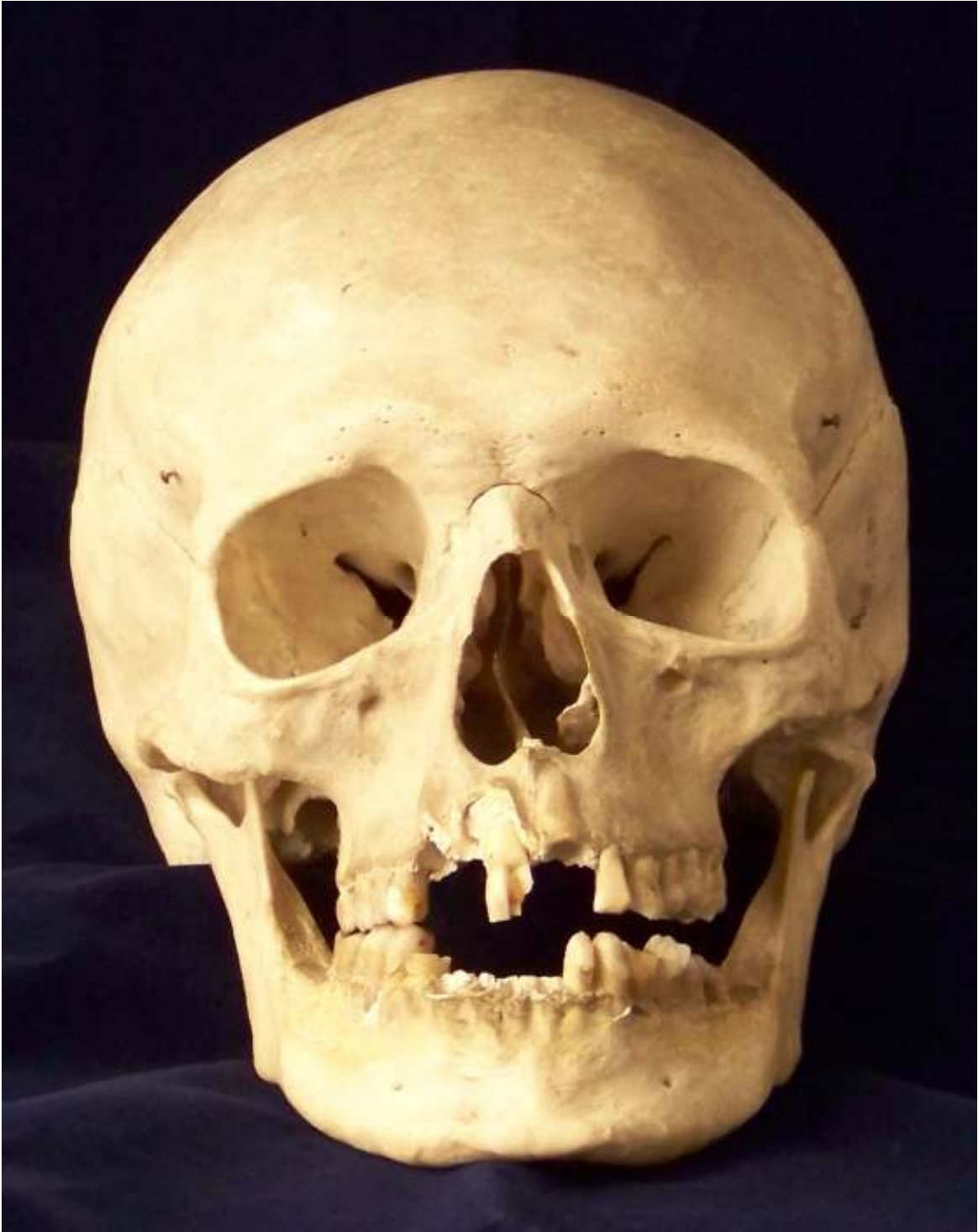Skull	Skeleton of the head, face, and lower jaw.
Cranium	A skull lacking its lower jaw.
Calvarium	A skull lacking the lower jaw and face.
Calotte	A braincase or skull cap.

Bones of the skull

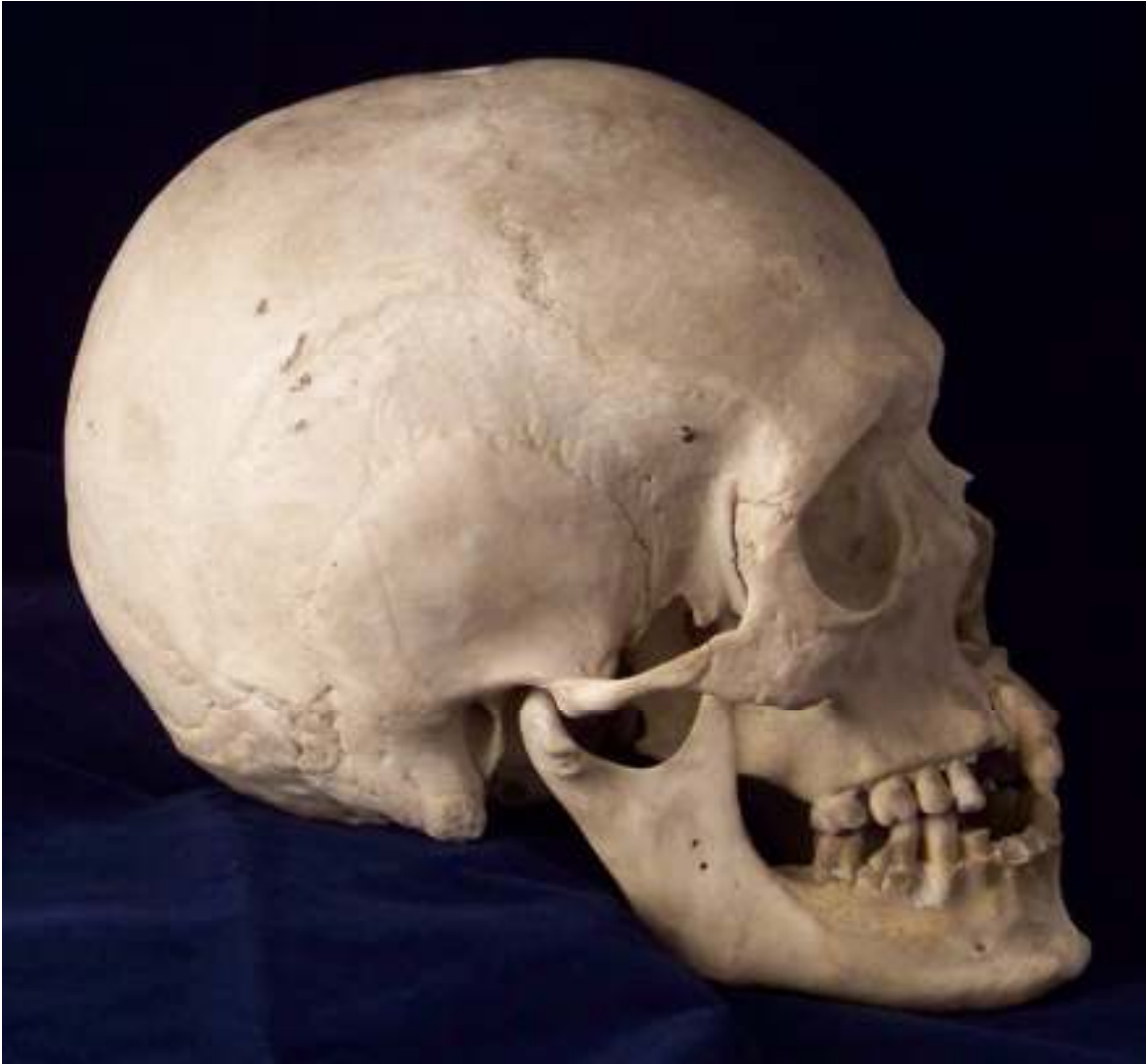The human skull is comprised of a total of 22 separate bones (excluding the ear ossicles and hyoid bone).

The cranial vault includes the following 8 bones:

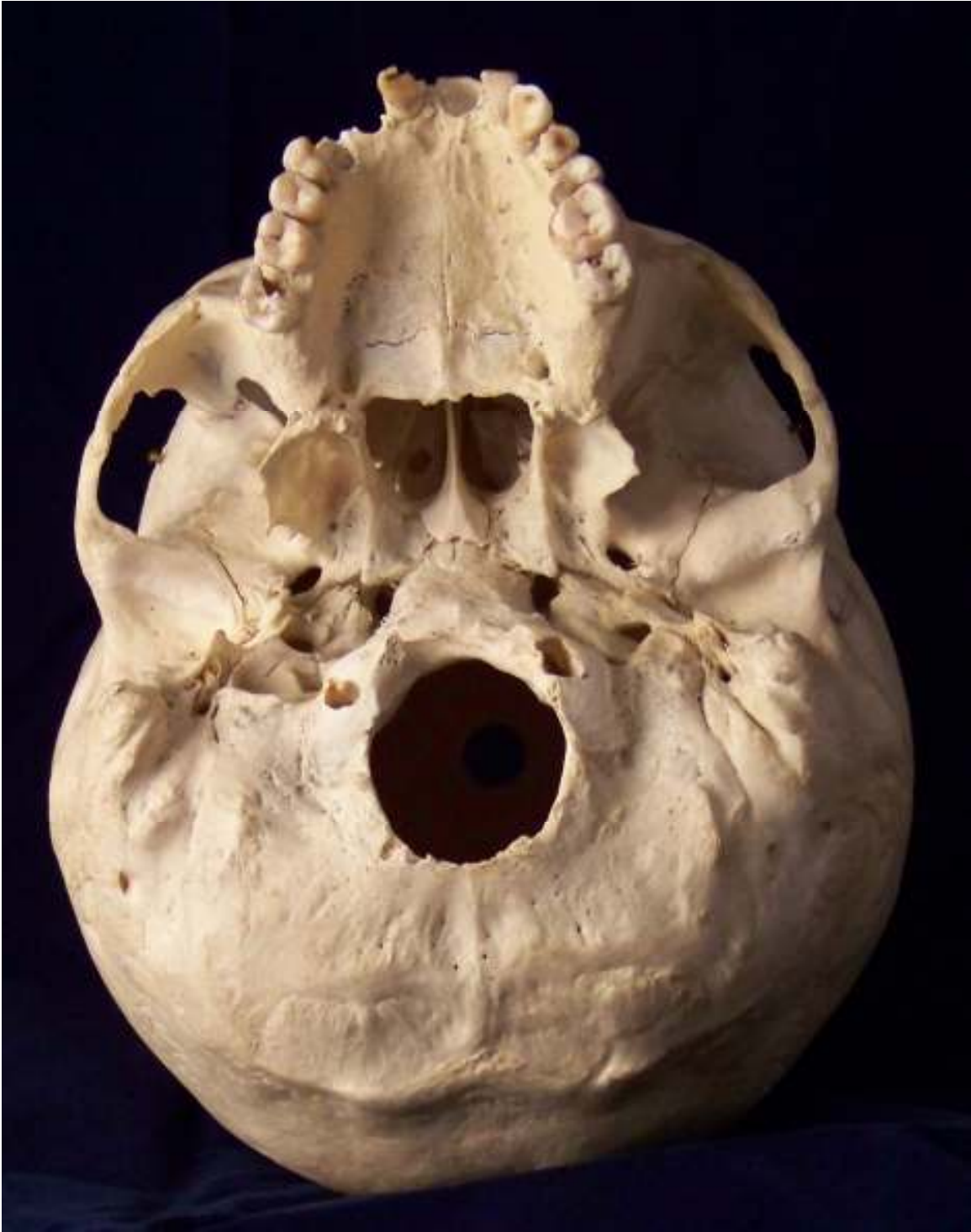1. Frontal
2. Parietals (2)
3. Occipital
4. Temporals (2)
5. Ethmoid
6. Sphenoid



Skull. Anterior view



Skull. Lateral view



Skull. Inferior view



Skull. Superior view

The face includes the following 14 bones:

- | | |
|-------------------|-------------------------------|
| 1. Lacrimals (2) | 5. Palatines (2) |
| 2. Zygomatics (2) | 6. Inferior nasal conchae (2) |
| 3. Maxillae (2) | 7. Nasals (2) |
| 4. Mandible | 8. Vomer |

Flat Bones of the Skull: Frontal, Parietal, Occipital, and Temporal

The flat bones of the skull making up the neurocranium or braincase have three basic structural layers. These comprise the outer and inner layers of compact bone and an intervening layer of spongy, cancellous bone called diploe.

The inner and outer layers tend to run parallel to one another and the bones are somewhat rounded with the inner layer being concave. The areas of bone thickening or ridging generally reveal the points of muscle or ligamentous attachment. Each of the flat bones of the skull will now be reviewed individually. You should familiarize yourself with each of their distinguishing morphological features.

1. Frontal Bone

The frontal is a single bone which is comprised of two main parts, a squamous or flat portion which forms the forehead and articulates with the parietal bones and an orbital portion which provides a roof for the two orbits. The supraorbital or brow ridges are bony ridges just above the orbits. These bony ridges are quite well developed in the skulls of some forms of fossil man, but are less pronounced in modern man. The supraorbital notches or foramina are grooves or openings for the passage of neurovascular structures.

A trace of the metopic or frontal suture may be noted in the midsagittal region of this bone. The glabella is a roughened region or a bulging prominence on the frontal bone above the nasal root at about the level of the supraorbital ridges. The frontal eminences are paired prominences in the anterolateral regions of the squamous portion of the frontal bone. These prominences may vary in size and degree of development in

individuals and are also a characteristic of sexual dimorphism. The median crest in the midline of the bone represents an area of muscle attachment and shows variability reflecting muscular robusticity of the individual. The paired temporal lines ascend superiorly and posteriorly from the zygomatic processes and constitute the superior-anterior margin of the temporal fossae. Endocranially, note the frontal crest.

2. Parietal Bones

The parietals are paired bones which form the roof and sides of the calvaria. They articulate with one another medially at the sagittal suture and anteriorly with the frontal bone at the coronal suture. The coronal and sagittal suture intersect at a point called bregma. The bregmatic fontanelle or “anterior soft spot” exists here in infancy. Posteriorly the parietals articulate with the occipital bone at the lambdoidal suture and laterally at its squamous margin with the temporal bones. It should be noted that the lambdoidal suture has a beveled-concave surface on the parietal bones.

The temporal lines continue from the frontal bone onto the parietals, representing areas of muscle attachment. A slight elevation may be present along the sagittal suture, but tends to be poorly developed in modern man. The parietal foramina are present near the midline posteriorly and transmit veins to the sagittal sinus inferiorly. Parietal foramina are a non-metric trait and may be present or absent on one or both sides. Additionally, size of the foramina should be noted as enlarged foramina may suggest heredity. Bilateral parietal eminences are prominences located postero-laterally on the parietal bones; they may or may not be present.

On the interior aspect of the parietal bones, depressions are present that are the result of the mid-meningeal arteries. To side the bone, hold the parietal in anatomical position and note that the arteries point superior and posterior; this will aid in identification of fragmentary finds. Also note the transverse sulcus or linear depression located at the inferior-posterior angle of the bone.

3. Temporal Bones

Each of these paired bones can be subdivided anatomically into a thin squamous portion which articulates with the parietal bone, a mastoid portion containing the mastoid sinuses and process, and a heavy-dense petrosal portion that contains the inner ear structure. The external auditory meatus or outer ear canal is readily apparent laterally. Projecting forward from each squama is the zygomatic process which articulates with the temporal process of the zygomatic bone. The zygomatic arch serves as an attachment for some of the muscles of mastication and is comprised of the zygomatic bone and the zygomatic process of the frontal, temporal and maxillary bones. In modern people this arch is delicate and relatively small in size and proportion.

The tympanic part and plate are located in the area surrounding the external auditory meatus. Note the mastoid crest located superior to the meatus.

Prominent, paired styloid processes may be seen projecting inferiorly and anteriorly directly below the mandibular fossae, which are also called the glenoid fossae. The condyles of the mandible articulate with the temporal bone at these fossae. The posterior margin of the mandibular fossa is delimited by a small projection known as the postglenoid process. For siding, position the mastoid process to point inferior with the zygomatic arch pointing anterior. The external auditory meatus is lateral and the petrous process is medial.

4. Occipital Bone

A single occipital bone forms the posterior-inferior aspect of the neurocranium and is divided anatomically into a posterior-superior flat squamous part, and anteriorly projecting inferior basilar part and paired lateral parts or jugular processes. The occipital bone articulates with the two parietal bones at the lambdoid suture. Small islands of bone within this suture are called wormian bones. Lambda is a term used to designate the intersection of the lambdoid and sagittal sutures. Occasionally a transverse suture is found which separates the apex of the squamous portion from the rest of the bone. The separate apical portion is then called an Inca bone; a trait found at an especially high frequency in Peruvian peoples. The Inca bone may be singular, bipartite, or tripartite.

The large opening in the base of the occipital bone is the foramen magnum which permits the emergence of the spinal cord from the skull. The paired, kidney-shaped articular surfaces, called the occipital condyles, are situated anterior and lateral to the foramen magnum. These condyles articulate with the atlas or first cervical vertebra.

Superior to the foramen magnum and in the midsagittal plane is the external occipital protuberance. This process tends to be more prominent in males and reflects muscular robusticity. Extending downward from this projection is the external occipital crest, also called the median nuchal line. Projecting laterally from the external occipital protuberance are the supreme and superior nuchal lines. A pronounced ridge or torus defined by the superior nuchal lines is uncommon in moderns but may be quite pronounced in some forms of fossil hominids. Below the superior nuchal lines the inferior nuchal lines extend laterally. The nuchal musculature has a strong attachment to these ridges of bone and they are therefore usually more pronounced in males; in many modern skulls of both sexes the lines are not sharply defined and may not be discernible.

The pharyngeal tubercle and fossa are two potential non-metric traits found on the basilar part of the occipital bone. Small foramina, the condylar and hypoglossal canals, allow the passage of neurovascular structures (hypoglossal nerve, etc) through the occipital bone. The condylar canal may be present, absent, or only a fossa on each side. The hypoglossal canal may be divided (internally or externally) or partially divided on each side.

Facial Bones, Sphenoid, Ethmoid, Ear Ossicles, and Hyoid

1. Zygomatic Bones

These paired quadrangularly shaped “cheek bones” are distinguished by their four separate processes. Three of the processes, the temporal, frontal, and maxillary are named according to their articulations. The fourth process which projects posteriorly from the frontal process is named the marginal process. The temporal process of the zygomatic bone and the zygomatic process of the temporal bone form the slender inferior-lateral portion of the zygomatic arches.

Occasionally, a suture separates the lower portion of the zygomatic. When present the inferior aspect of the bipartite zygomatic is termed the Os japonicum.

For siding, the concave surface is anterior, the masseter attachment is inferior, the orbital rim is smooth and rounded, and the sharp zygomatic process points posteriorly, and the long jagged articulation is medial.

2. Maxillary Bones

The paired maxillae contain the upper row of teeth, enclose the nasal cavity, form a portion of the orbital floors and form the anterior roof of the mouth. These bones form the major portion of the upper facial skeleton and, with the exception of the mandible, articulate with all of the other facial bones. The bodies of the maxillae contain the large maxillary sinuses which may be seen on a disarticulated skull specimen.

Four processes extend from the body of the maxillary bone. These comprise the zygomatic processes articulating with the zygomatic bone, the tooth bearing alveolar process (the alveolar arch is formed through the union of the two alveolar processes), the frontal process lateral to the nasal bone and superior to the nasal cavity, and the palatine processes which together form the greater portion of the hard palate. The infraorbital foramen located inferior to the orbit transmits cutaneous nerves to the face. Infraorbital sutures run between the infraorbital foramina and inferior orbital margins. Presence of these sutures is variable, present or absent on either side. The anterior nasal spine, subnasal groove, and nasal sill are all present at the anterior-inferior margin of the nasal cavity.

For siding, the dental arcade is inferior and sharp outline of the nasal aperture medial.

3. Nasal Bones

The thin paired nasal bones form the bridge of the nose and roof of the nasal cavity. They may vary considerably in size and configuration, shape of the suture should always be noted.

4. Inferior Nasal Conchae

These paired structures comprise separate hook-like projections of bone which extend down from the lateral walls of the nasal cavity. The inferior nasal conchae articulate with the ethmoid, lacrimals, maxillae, and palatine bones throughout their extensive attachments.

5. Lacrimal Bones

The paired lacrimal bones are rectangular-shaped, small plates of bone located in the anterior medial aspect of the orbits. As the name implies these bones seat the lacrimal or tear ducts. A fine ridge of bone running superiorly-inferiorly through the central portion of this bone is called the posterior lacrimal crest. The anterior lacrimal crest is a portion of the maxillary bone.

6. Vomer

This single bone is a thin plough-shaped structure which forms the inferior-posterior aspects of the nasal septum. The vomer divides the nasal cavity in the midsagittal plane. Frequently this bone is deviated to one side when viewed anteriorly. The small lateral projections superiorly and posteriorly are the alae or wings of the vomer.

7. Palatine Bones

The paired palatine bones form the posterior portion of the hard palate, a part of the floor and lateral walls of the nasal cavity and a portion of the orbital floor. Characteristic anatomic landmarks are the small, posteriorly projecting posterior nasal spine and the elevated anteriorly projecting bony ridge in the midline of the palate, called the palatine torus.

8. Mandible

The mandible or lower jaw is a large, strong, that articulates with the cranium and works in conjunction with the maxillae to masticate food. Anatomically it can be divided into a parabolically curved body containing the lower teeth and two vertically extending

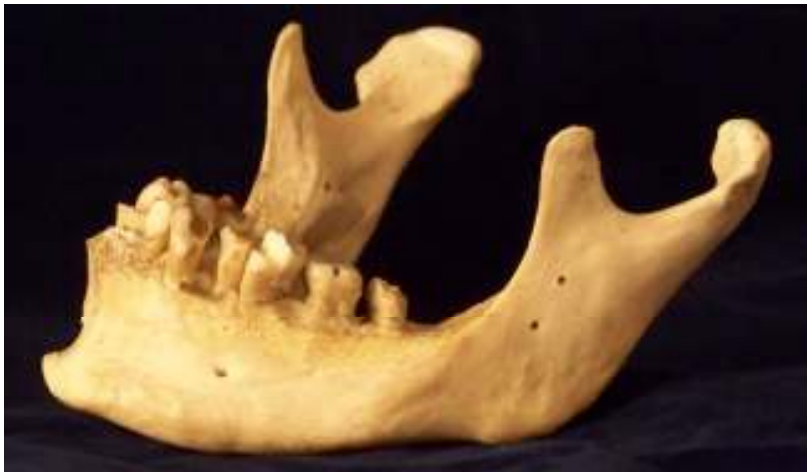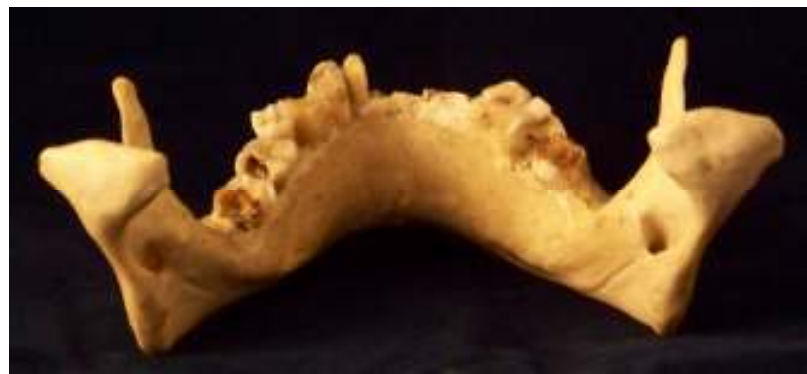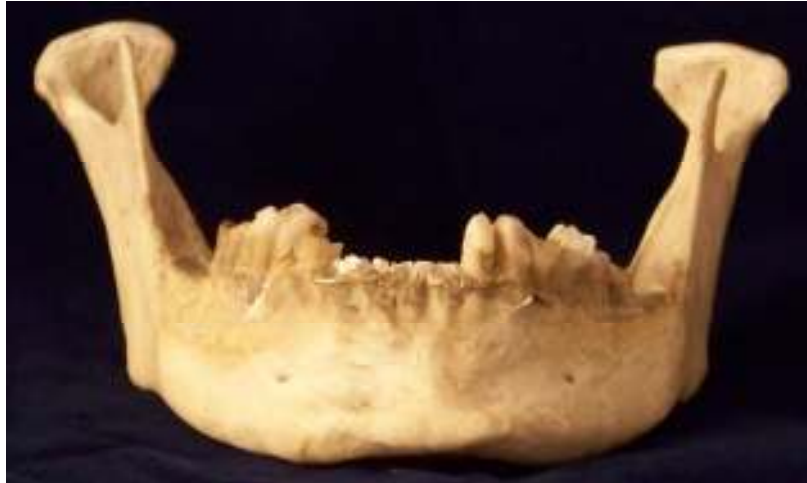rami. The ramus on each side is composed of two distinct processes separated by the mandibular notch. The most anterior is the coronoid process which gives attachment to the muscles of mastication. Posteriorly, the condyloid processes project superiorly to articulate with the mandibular fossae of the temporal bone. At the posterior and inferior of the mandible are located the gonial angles where the body and rami join. A mandibular symphysis is apparent during infancy, seen at midline on the anterior aspect of the mandibular body. The two halves of the mandible fuse by six months of age.

Projecting out below the symphysis is the mental tubercle or eminence which is an anatomic structure unique to man. The alveolar part contains the teeth and the paired mental foramina are found perforating the body of the mandible, located on the anterior aspect of the body and lateral to the mental eminence.

When viewing the posterior aspect of the mandible, several distinctive features can be seen. The mandibular foramen is located posterior and superior on the internal aspect of the mandible. Anterior to the mandibular foramen is the lingula, represented by a small tongue of bone. Rough, ridge-like attachments for the pterygoid muscles are found in the region of the inner aspect of the gonial angles. The mylohyoid ridge courses from posterior to anterior on the inner aspect of the mandibular body. Finally, the mental spine can be seen projecting posteriorly from the region of the symphysis where the two halves of the mandible articulate anteriorly.

9. Sphenoid

The single sphenoid bone is situated deep in the facial skeleton. This bone separates the face from the neurocranium and provides a seat called the sella turcica (or Turkish saddle) for the pituitary gland. The median or central part of this bone is called the body of the sphenoid. Extending laterally from the body are two sets of wings. The small wings form the posterior portions of the orbits while the large wings form the inferior and lateral portions of the orbits. Note that the lateral surface of the sphenoid also makes up part of the cranial vault, located just anterior to the temporal bones. On the inferior aspect of the sphenoid are projecting pointing downward called the pteryoid processes. These processes comprise lateral and medial plates; the most inferior “hook”



Mandible. Top anterior view, middle posterior view, bottom lateral view.

of the medial plate is called the hamulus of the pterygoid. Additionally, the medial plate comprises part of the nasal walls.

Perforating the root of the large wing inferiorly are three foramina. These foramina are the foramen rotundum (for the maxillary nerve), the foramen ovale (for the mandibular nerve), and the foramen spinosum (for the middle meningeal artery). The foramen rotundum is the most medial and anterior of the three; ovale is the second most medial (and oval in shape), and the spinosum is the most lateral (and round in shape). The optic foramen (for the optic nerve) perforates the body of the sphenoid. Between the large and small wings the large superior orbital fissures are apparent.

10. Ethmoid

This single bone is essentially spongy in character and is located at the anterior aspect of the base of the neurocranium, between the two orbits. The ethmoid can be divided into four main parts: the perpendicular plate, horizontal plate, and two lateral masses. The perpendicular plate forms the upper portion of the nasal septum while the horizontal or cribriform plate is situated at a right angle to the perpendicular plate and the roof of the nasal cavity. Many small perforations pass through the cribriform plate which allows passage for branches of the olfactory (smell) nerve. An extension called the crista galli (cocks comb) is located centrally on the superior aspect of the cribriform plate. The paired lateral masses contain the conchae and the ethmoidal sinuses, as well as making up the postero-medial portion of the orbits.

11. Ear Ossicles

The three small bones of the middle ear are frequently lost during the excavation process of archaeological remains. These three bones are the incus (anvil in shape), malleus (hammer like in shape), and the stapes (stirrup shaped).

12. Hyoid

This single horseshoe-shaped bone floats freely in the soft tissue of the neck just above the larynx. The hyoid bone has no bony articulations but gives support and attachment to the stylohyoid ligaments and pharyngeal musculature. This bone is divided

anatomically into a central body and paired major and minor cornua or horns. If found broken in the area of the greater horns, strangulation or hanging are suggested.

Cranial Sutures

Sutures are the fine, irregular lines of junction between articulating cranial bones. The bones of the skull originate through intramembranous or endochondral bone formation. Ossification gradually progresses until only the suture lines with their thin layer of interposing fibrous tissue remain. Fontanelles or “soft spots” (membranous areas) in an infant represent areas where ossification of the cranial bones has not yet occurred.

Throughout adult life the sutures gradually undergo closure and are bridged by bone union. The rates of closure are fairly constant in time of occurrence and sequence, though the age ranges are broad. Still, the determination of suture closure is one of the basic methods of assessing skeletal age in adult specimens. There are many regionally defined sutures in the skull, as follows:

1. Coronal suture, runs laterally across the top of the skull separating the frontal and parietal bones.
2. Sagittal suture, runs longitudinally across the skull from the occipital to the frontal bone and separates the parietal bones from one another.
3. Lambdoid suture, is an inverted “V” in shape and separates the occipital bone from the parietals. This suture terminates laterally on each side at the temporal bone.
4. Squamosal sutures, roughly semicircular in configuration and separate the parietal bones from the superior portion of the temporal bones. These sutures extend from the sphenoid bone anteriorly to the supra-mastoid crest posteriorly.
5. Parieto-mastoid sutures, continuous posteriorly with the squamosal suture, separating the parietal bone from the mastoid region of the temporal bone.
6. Occipito-mastoid sutures, separate the occipital bones from the mastoid regions of the temporal bones.
7. Spheno-temporal sutures, separate the sphenoid and temporal bones.

8. Spheno-occipital suture (also called the basilar suture), separates the sphenoid and occipital bones.
9. Spheno-parietal sutures, separates the sphenoid and parietal bones.
10. Spheno-frontal sutures, separates the sphenoid and frontal bones.
11. Fronto-nasal suture, separates the frontal and nasal bones.
12. Internasal suture, separates the two nasal bones from one another.
13. Fronto-zygomatic suture, separates the frontal and zygomatic bones.

Non-Metric Traits of the Skull

Cranium

Apical bone	Accessory bone located at the intersection of the sagittal and lambdoidal sutures (lambda).
Asterionic bone	Accessory bone located at the intersections of the lambdoidal and squamosal sutures.
Auditory exostosis	Bony nodule located in the external auditory meatus. Note if the nodule occludes $\frac{1}{4}$, $\frac{1}{2}$, $\frac{3}{4}$, or the entire meatus.
Bipartite occipital condyles	Division of the occipital condyles in the area of fusion between the basilar aspect of the occipital and the squamous portion of the occipital.
Bregma bone	Accessory bone located at the intersection of the coronal and sagittal sutures (bregma).
Condylar canal	Foramen or canal located posterior to the occipital condyles. Note if the canal is complete or partial. To measure completeness, use a thin pipe cleaner and gently try to insert it into the canal.

Divided hypoglossal canal	Foramen or canal located at the anterior end of the occipital condyles (beneath the condyles). Note if the canal is divided into two canals; there may also be a partial division. When noting division, observe if the bony spicule is within the canal or on the lateral or medial aspects.
Epiteric bone	Accessory bone located at the intersection of the frontal, parietal, sphenoid, and temporal bones.
Foramen ovale	Located on the inferior aspect of each of the greater wings; they are the only holes (foramina) of the sphenoid that are oval in shape.
Foramen rotundum	Most anterior and medial of the sphenoidal foramina; circular holes in each of the cranial fossae of the greater wings.
Foramen spinosum	Located on the inferior aspect of each of the greater wings, these foramina are the most lateral foramina on the sphenoid and generally the smallest of the circular holes in the sphenoid.
Frontal grooves	Supraorbital, shallow grooves which are tracks for vessels and nerves. May be seen running into the supraorbital notch/foramen. May or may not be present.
Inca bone (bipartite, tripartite)	A transverse suture divided the squamous portion of the occipital, creating an accessory bone. The Inca bone is seen at a higher frequency among South American populations. The Inca bone may be singular, bipartite or tripartite. If bipartite an vertical suture will separate the bone into two pieces, if tripartite two vertical sutures will separate the bone into three pieces.

Infraorbital foramen	Additional foramen located medially, inferior to the lower margin of the orbit on the maxillary bone. One is always present.
Infraorbital suture	Accessory suture located medially, inferior to the lower margin of the orbit on the maxillary bone. Generally runs between the margin of the orbit and the infraorbital foramen. May be either complete or partial.
Inion spike	Ridge or inferiorly projecting hook of bone in the region of the external occipital protuberance; most often seen in males.
Marginal tubercle	A protuberance in the region of the masseteric muscle attachment on the inferior margin of the zygomas.
Mastoid foramen	Single or multiple foramina located within the occipitomastoid suture, or near the suture on either the temporal or occipital. Number and location should always be noted during observation.
Maxillary torus	Bulging protuberance located on the lingual margins of the alveoli near the maxillary molars. Generally, maxillary tori are associated with culture groups that use their teeth as tools.
Metopic suture	Divides the frontal bone, located at midline. Generally closes by eight years of age. If present, it should be scored as complete or partial. (Mann and Hunt 2005)
Os Japonicum	Additional suture dividing each zygomatic into two pieces.
Ossicles or wormian bones	Aberrant growth patterns may be manifested by sutural complexities represented by small islands of bone.

Pacchionian pits	Pits with sharply defined margins located on the frontal and parietals, vary in size from small to large. (Mann and Hunt 2005)
Palatine torus	Bulging protuberance located on the along the lingual aspect of the palatine suture. Generally, a palatine torus is associated with culture groups that use their teeth as tools.
Parietal foramen	Single foramen located on the posterior aspect of the parietal along the saggital suture near obelion. Each parietal may display a foramen, although the foramen may be either absent or within the suture itself. Very large or misshapen parietal foramen are sometimes observed, and should be recorded.
Parietal notch bone	Extrasutural bone located in the squamosal suture; anterior to asterion. May be unilateral, bilateral, or absent.
Pharyngeal tubercle/fossa	Round depression or smooth projection located in the center of the basilar aspect of the occipital, on the ectocranial surface.
Pterygo-alar bridge/spur	Bridge or spicule of bone originating either on the lateral pterygoid lamina or on the lateral aspect of the foramen ovale.
Pterygo-spinous bridge/spur	Bridge or spicule of bone origination either on the lateral pterygoid lamina or on the medial aspect of the foramen ovale.
Supraorbital foramen	Complete foramina located along the superior margins of the orbits (anterior frontal). Completeness can be measured by passing a thin pipe cleaner through the foramina. Number should be observed for each orbit.

Supraorbital notch

Notches located along the superior margins of the orbits (anterior frontal). Number should be observed for each orbit.

Trochlear spine

Small, sharply-curved bony projection within the orbit; located on the medial aspect of the frontal within the orbit. May also be represented by a notch without the bony projection. Trait may be unilateral, bilateral, or absent (trait is rare). (Mann and Hunt 2005)

Tympanic dehiscence

Hole perforating the tympanic plate or the temporal bone; located on the inferior aspect of the external auditory meatus. Size should be observed if present. May be bilateral, although presence of the trait is rare. (Mann and Hunt 2005)

Zygomatico-facial foramen

Single or multiple foramen located on the convex surface of the zygomatics, inferior to the orbital margin. This trait may also be absent; number and size (large or small) should be noted during observation.

Mandibular**Mandibular torus**

Bulging protuberance located on the lingual margins of the alveoli near the mandibular molars. Generally, mandibular tori are associated with culture groups that use their teeth as tools.

Mental Foramen

Foramina located on each side of the labial aspect of the mandible inferior to the second premolar. Usually singular, but may be multiple.

Mylohyoid bridge

Bony bridge crossing the mylohyoid sulcus; may be partial or complete.

Articulations of the Cranial Bones with One Another

Sphenoid

Vomer
Ethmoid
Frontal
Occipital
Parietal
Temporal
Zygomatic
Palatine

Occipital

Parietal
Temporal
Sphenoid
Atlas

Frontal

Sphenoid
Parietal
Ethmoid
Lacrimal
Nasal
Zygomatic
Maxilla

Parietal

Occipital
Frontal
Temporal
Sphenoid
Parietal

Lacrimal

Frontal
Ethmoid
Inferior nasal concha
Maxilla

Maxilla

Frontal
Ethmoid
Zygomatic
Inferior nasal concha
Vomer
Lacrimal
Maxilla
Nasal
Palatine
Mandible

Mandible

Temporal
Maxilla

Zygomatic

Frontal
Sphenoid
Maxilla
Temporal

Temporal

Occipital
Sphenoid
Parietal
Zygomatic
Mandible

Vomer

Sphenoid
Ethmoid
Palatines
Maxilla

Ethmoid

Sphenoid
Frontal
Maxilla
Palatines
Vomer
Inferior nasal concha
Lacrimal

Inferior Nasal Concha

Ethmoid
Lacrimal
Maxilla
Palatine

Nasal

Nasal
Maxilla
Frontal

Palatine

Sphenoid
Ethmoid
Maxilla
Inferior nasal concha
Vomer
Palatine

Landmarks and Measurements of the Skull

Standardized landmarks and measurements of the skull and post-cranium are necessary in order to compare validity as part of the scientific method. These measurements can be used to determine sex, biological affinity, stature, modernity, and specific facial features in the remains of an unknown individual. Therefore, it is necessary to use agreed upon landmarks on the skull from which the measurements can be taken. To increase reliability, an individual researcher should take the same measurements on an individual(s) several times over the course of a few days to estimate intra-observer error. Research partners should undertake the same process to determine what the error rate may be between researchers, inter-observer error. The following list of landmarks and basic measurements will aid in learning standardized methodology used in osteological research.

Landmarks

Alveolare	The bony crest located between the central maxillary incisors.
Alare	Determined using sliding calipers placed on the most lateral margins of the nasal aperture.
Basion	Point located on the anterior border of the foramen magnum.
Bregma	The point where the sagittal suture meets the coronal suture anteriorly.
Dacryon	Located in the medial aspect of the orbits, the point where the maxilla, lacrimal, and frontal meet.
Ectoconchion	Located at the intersection of the frontal and zygomatic, on the medial aspect.
Euryon	Determined using spreading calipers placed on the posterior parietals at the greatest breadth.
Frontotemporale	Located on each of the temporal lines of the frontal in the area of greatest constriction.
Glabella	The point superior to the nasal bones, between the supraorbital ridges.

Gnathion	The central point on the inferior aspect of the mandibular body in the region of the mental eminence.
Infradentale	The bony crest located between the mandibular central incisors.
Lambda	The intersection point of the lambdoidal suture and the sagittal suture.
Nasion	The point located most superiorly where the nasal bones meet.
Nasiospinale	The point where the midsagittal plane intersects the inferior margin of the nasal aperture.
Opisthion	The most medial point on the posterior aspect of the foramen magnum.
Opisthocranium	Most posterior aspect of the skull, excluding the area around the external occipital protuberance.
Orbitale	The most inferior point on the lower orbital margin.
Prosthion	On the upper alveolar process, this is the most anterior point at midline.
Zygion	Determined using spreading calipers placed on the most lateral aspects of the zygomatic arches.

Measurements

Basion-Bregma	Taken using the spreading calipers; one end of the calipers is placed on the medial aspect of the rim of the foramen magnum (basion) and the other end is placed at intersection of the coronal and sagittal sutures (bregma).
Bizygomatic	Taken using the spreading calipers; one end of the calipers goes to the most lateral aspect of each of the zygomatic arches (zygoma to zygoma).
Cranial breadth	Taken using the spreading calipers; one end of the calipers goes to the most lateral aspect of each of the parietals (euryon to euryon).

Cranial length	Taken using the spreading calipers; one end of the calipers is placed just superior to the frontonasal suture on the most anterior aspect of the frontal (glabella), while the other is placed at the most posterior aspect of the skull (opisthocranium).
Minimum frontal breadth	Taken using the spreading calipers; one end of the calipers is placed on each of the temporal lines of the frontal in the area of greatest constriction (frontotemporale to frontotemporale).
Nasal breadth	Measurement is taken from alare to alare, to obtain the maximum breadth; use spreading calipers.
Nasal height	Measurement is taken from nasion to nasiospinale; use sliding calipers.
Orbital breadth	Measurement is taken from dacryon to ectoconchion; use spreading calipers.
Orbital height	Measurement is taken perpendicular to the horizontal axis of the orbit; use spreading calipers.
Total facial height	Measurement is taken from nasion to gnathion with teeth in occlusion; use sliding calipers.
Upper facial height	Measurement is taken from nasion to alveolare (does not include height of the mandible); use sliding calipers.

Estimating Age in the Skull

Determining age at death is largely based upon dental eruption, dental calcification, dental wear, suture fusion, epiphyseal union of the postcranial bones, and degenerative changes (i.e. arthritis). Size and general appearance have little utility. In general, the older the individual at the time of death, the less accurate is the age estimate. Determining age requires comparison with tables of developmental norms.

There can be considerable variation in the degree in which individuals vary from the average of development. Tables of norms should thus be regarded only as approximations.

Dental Calcification, Eruption, and Wear

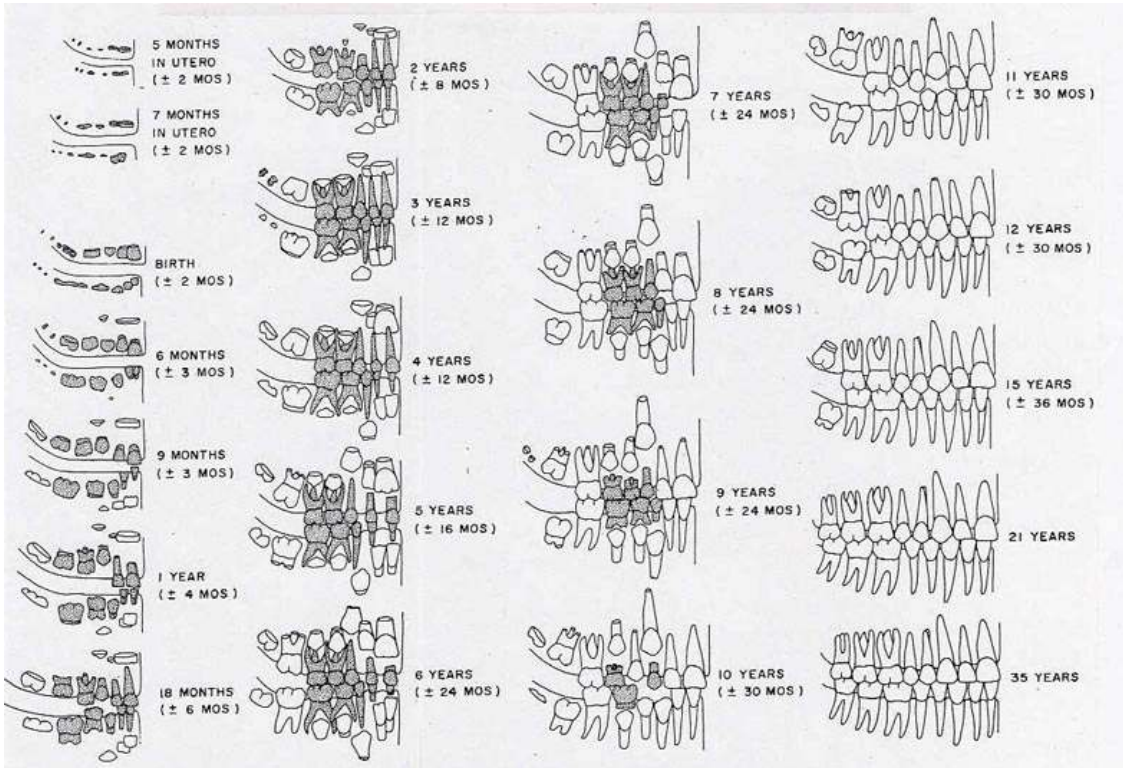
Development of the dentition occurs at approximately 3-7 months in utero and continue until the late teens or early twenties. Radiographic examination of the dentition shows the development of the crown, root, and closure of the root, which can be used to determine age. For further reading on dental calcification see Moorrees et al. (1963), Age Variation of Formation Stages for Ten Permanent Teeth in the Journal of Dental Research, 42:1490-1502.

Eruption of the teeth into the mouth begins to occur around nine months of age. Each tooth has a general age of eruption, but this can vary from a few months to a few years as each child develops along a different trajectory. Ubelaker (1978) prepared a diagram for use in aging children going through dental eruption, this diagram is widely used in the discipline to estimate age at death. A quick table of eruption is listed below.

Dental eruption sequence

1.	Deciduous teeth present	8 mon. – 6 years
2.	First molar erupted	6 years
3.	Second molar erupted	12 years
4.	Third molar erupted	18-21 years
5.	Medial incisors erupted	6-11 years

Dental wear or attrition occurs as the teeth erupt into the mouth. As an individual chews the topmost layer of tooth is ground off. As an individual ages, the amount of wear increases first through the enamel and then to the dentine. Individuals of advanced age or those eating coarse foods may wear the teeth to the point the crown is absent, and the root then becomes the masticatory surface. Due to the variability in the texture of foods eaten, dental wear may make an individual appear older or younger. For example, modern populations consuming extremely soft foods will show a much reduced dental wear. Other activities may also be responsible for tooth wear including bruxism and using the teeth as tools. Prehistoric tool use included working hides and doing light



Dental Eruption (Ubelaker 1978)

Age Period (years)	About 17-25			35-55			55-65			About 65		
	M1	M2	M3	M1	M2	M3	M1	M2	M3	M1	M2	M3
Wear patterns			Dentine not exposed. There may be slight enamel polishing							Any greater degree of wear than in the previous columns NB. Very unequal wear sometimes occurs in the later stages 		

Dental Wear (Brothwell 1981)

retouch on lithics, while today teeth may be used as tools to open packaging. Brothwell (1981) developed a general system for dental wear that is helpful in aging older individuals.

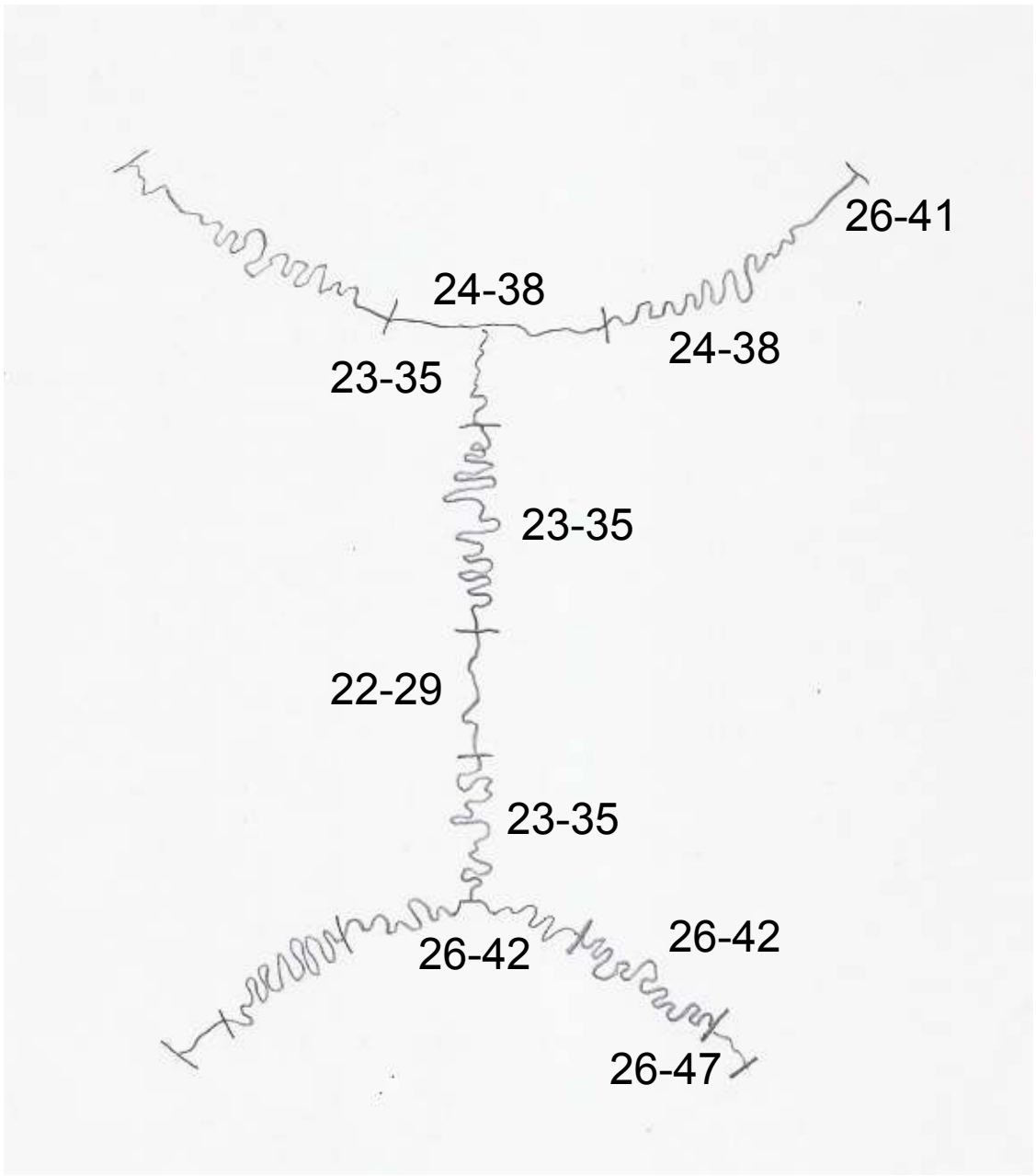
Aging Adult Remains Through Suture Closure

Once dental eruption is complete, aging of specimens becomes more difficult. Degenerative changes that are visually observable, including arthritis and dental wear, are two of the most effective methods which can be used to determine the age of an adult. Cranial suture closure may also be used, but in general will provide broad ranges into which a specimen will fall. Sutures should be recorded as unobservable, open (no evidence of closure), minimal closure (up to 50% closure observed), significant closure (mostly fused, but not complete), complete obliteration (totally fused) (Buikstra and Ubelaker 1994).

- | | | |
|----|---|-------------|
| 1. | Fusion of basilar suture | 17-23 years |
| 2. | No fusion at spheno-temporal joint | 17-29 years |
| 3. | Fusion beginning at Spheno-temporal/spheno-parietal joint | 29-65 years |
| 4. | Spheno-temporal/spheno-parietal joint fused | 65+ years |

Degenerative Change in the Skull

A few degenerative changes exist that can be used in aging including biparietal thinning, alveolar resorption, and arthritis of the occipital condyles and mandibular fossae. Biparietal thinning begins on the external table of the lateral and posterior aspects of the parietals. The parietal bosses will appear flattened in nature (Mann and Hunt 2005). This is generally seen in individuals of advanced age, likely 50 years or older. Alveolar resorption is the product of tooth loss, decrease in bone density associated with age, and also periodontal disease. The alveoli shrink, and as teeth are shed the sockets fill in. The two areas where movement occur in the skull are the occipital condyles and mandibular fossae. At these articulation sites osteophytic lipping or erosion may be present, both of which suggest an age of 35 years of older. Lipping is represented by small ridges or spicules of bone within or around the margins of the surface. Erosion is



Cranial Suture Closure

seen as pitting with irregular margins within the surface area, increase porosity will also be seen around and within the erosive area.

Estimating Sex in the Skull

Physical anthropologists are often called upon to identify skeletal remains; this may be for archaeological or forensic remains. Due to substantial individual and populational variation, the reliability of such attempts is rather limited. Moreover, much practice and guidance is required to achieve reliable conclusions. The following is meant to provide only some familiarity with the methods employed.

While virtually all bones display some sexual dimorphism, the pelvis is the most reliable for identification. Using the skull alone is less accurate. In cases of adult crania with which there is neither lower jaw, nor any other part of the skeleton, the diagnosis is about 80 percent reliable. This proportion rises to 90 percent where a well-preserved lower jaw is present; and will reach 96 to 98 percent when a whole skeleton is present. Although there will still remain skeletons which, even though complete, show such ambiguous sexual characteristics that it will be impossible to identify them as either male or female with certainty. The following are cranial traits used in sex assessment:

Overall size – Larger in males; smaller in females.

Muscle attachments – Stronger in males exhibited by roughening; females are generally more smooth overall.

Cranium

External occipital protuberance – More pronounced in males; rounded and smooth in females.

Forehead – Retreating in males; smooth, round, more vertical and better developed frontal eminences in females.

Glabella – Protrudes in males; smooth in females.

Mastoid process – Large in males; small in females.

Palate – Males are larger and broader; females display less depth.

Supra-mastoid crest – Larger and extend past the external auditory meatus in males.

Supraorbital margins – Rounded and thick in males; sharp and thin in females.

Supraorbital ridges – More pronounced in males; flat and smooth in females.

Zygomatic bones – higher, stouter, and rugged in males.

Zygomatic processes – Heavier in males; more slender in females.

Mandible

Mental eminence – Square and broad in males; v-shaped and narrow in females.

Gonial angle – Less obtuse in males (stouter, rougher, and more everted angles); an angle over 125 degrees suggests female sex.

Estimating Biological Affinity in the Skull

Assessing biological affinity in the skeleton cannot be done with a promise of great accuracy. Nonetheless, legal authorities often wish to have as much information for identification as possible. This is especially true when a burial is found, and it is suspected that the person was the victim of foul play.

Bear in mind that in all populations male skulls tend to be more rugged than females, and that this will complicate the assessment. Also remember that these characteristics are merely typical and not diagnostic, as they may be seen at variable frequencies in all human populations.

The following may be used in assessment of biological affinity:

Australian Aborigine

Long cranium, deep set orbits, well developed brow ridges, pronounced post-orbital constriction

San Bushman

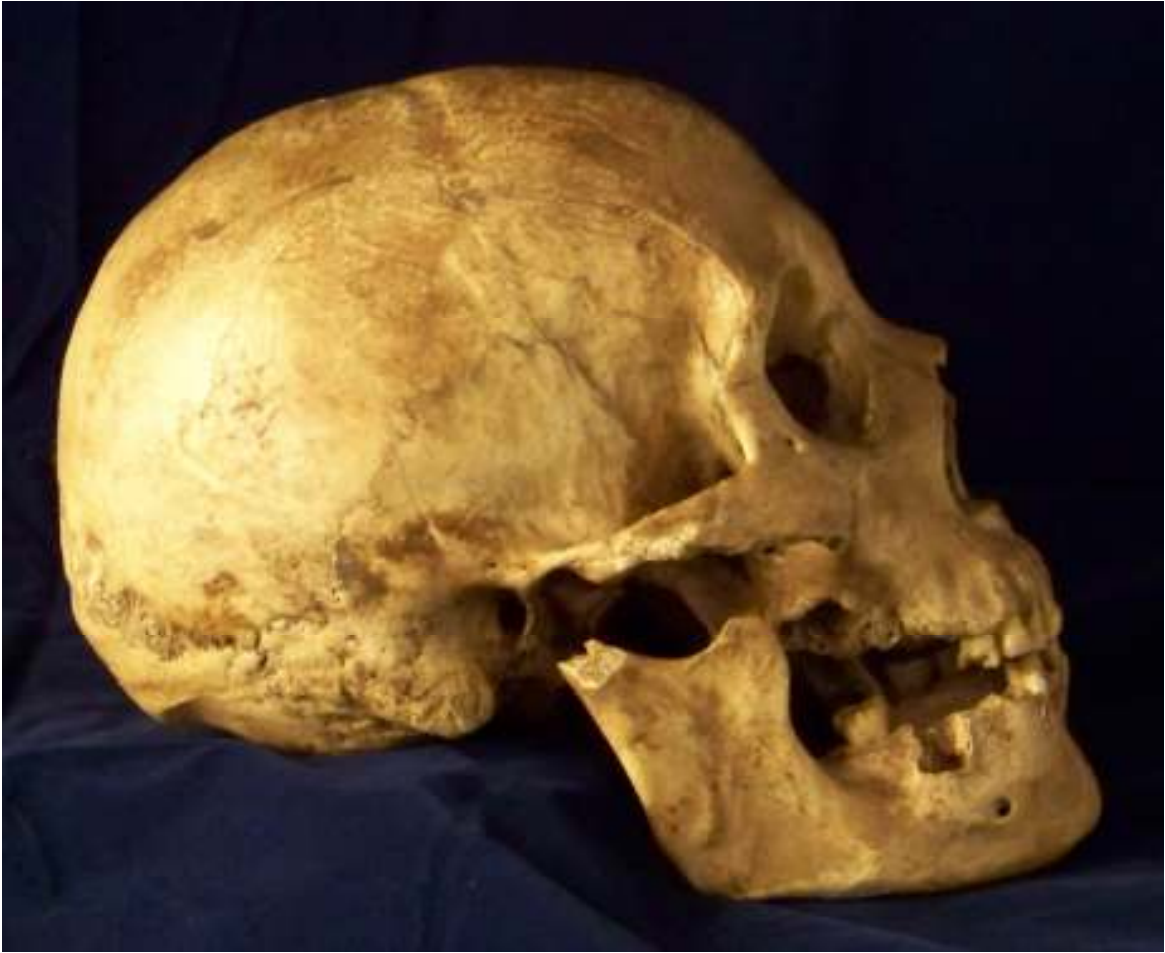Very short face, extremely prominent forehead, gracile skull form

American Indian

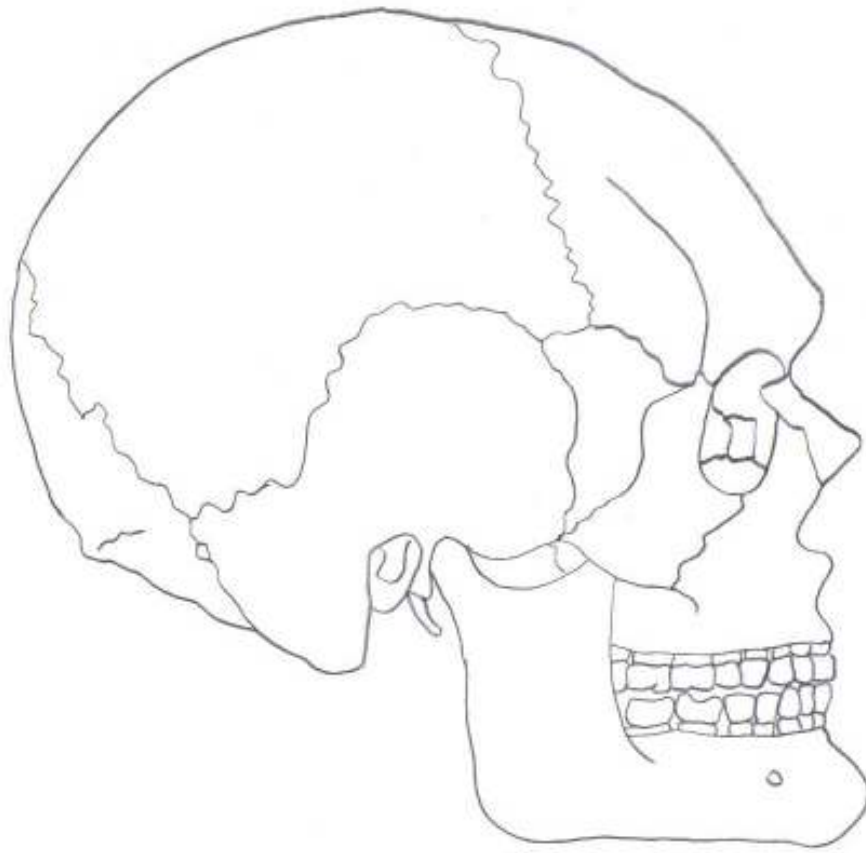
Round cranium, nasal overgrowth, shovel-shaped incisors, edge to edge bite, central incisors rotated toward midline, prominent zygomatics, smooth orbits, straight face

American Black

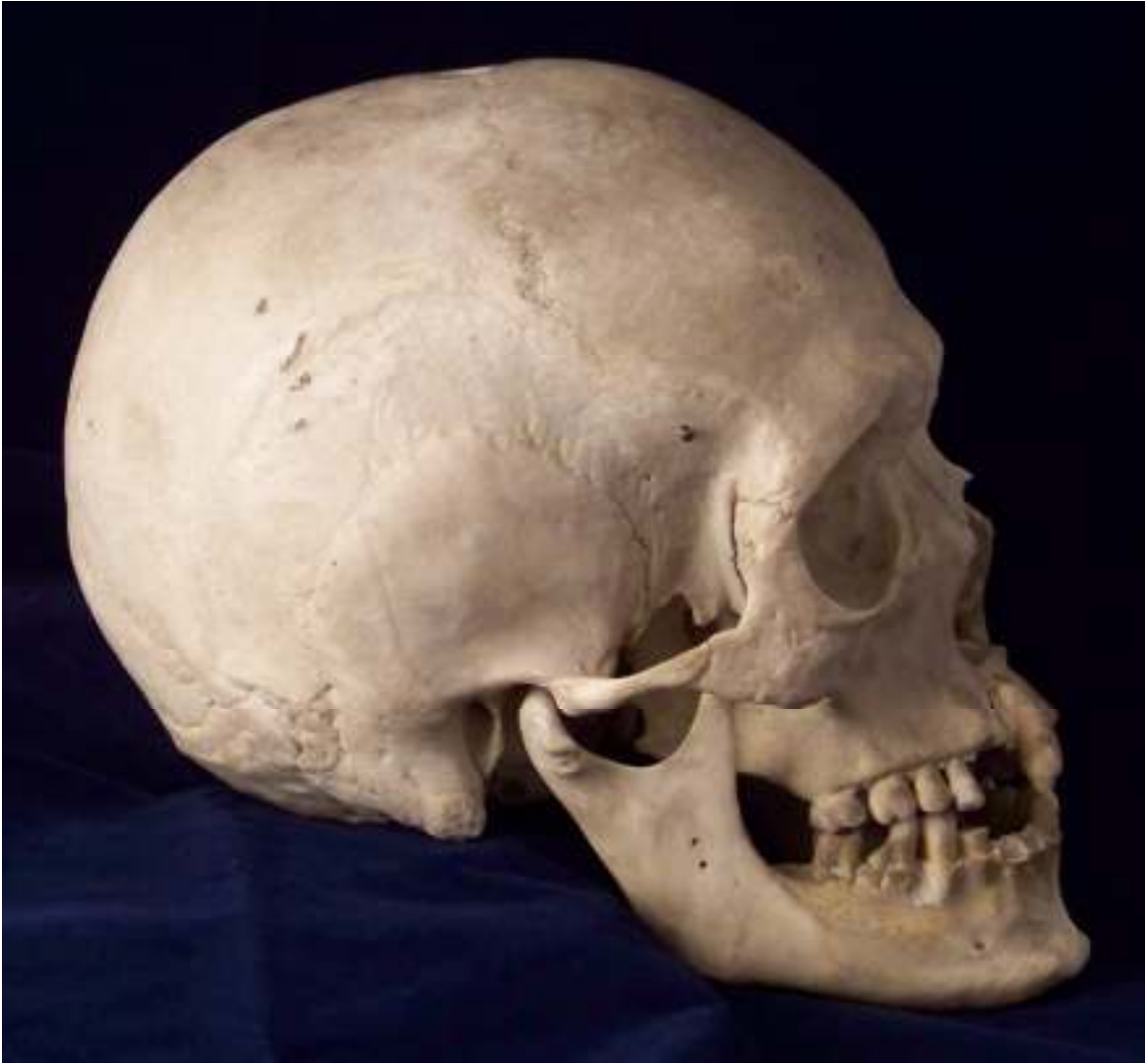Long cranium, short face, smooth brow ridges, wide nasal aperture, nasal gutter, bregmatic depression, overbite, alveolar prognathism.



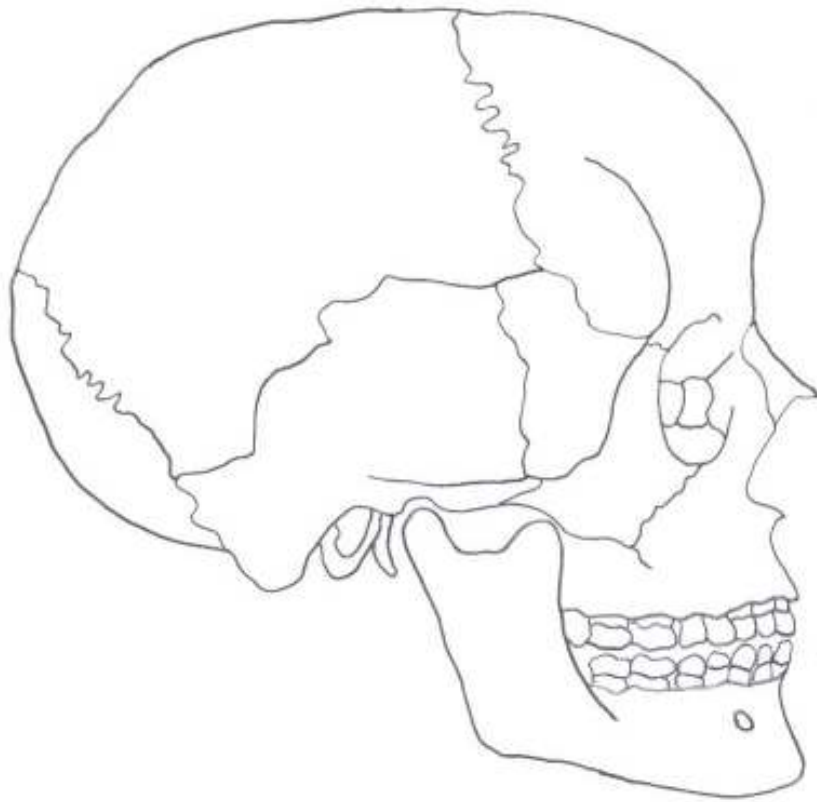
Male Skull



Male Skull



Female Skull



Female Skull

Euro-American

Variable cranial shape, variable size, narrow and orthognathic face, nasal sill, narrow nasal aperture, highly angled nasals, overbite, highest frequency of Carabelli's cusp.

Cranial Deformation & Cranial Trauma

Cranial deformation – Two major types of cranial deformation may be observed: artificial and accidental. Artificial deformation is practiced purposely by a number of cultures globally, and can be meant to show social status, ethnic affiliation, or beauty. Pressure may be placed on the frontal, occipital, or circumferentially. Accidental deformation occurs when an infant is strapped to a cradle board for a long period of time, or if an infant is allowed to lay flat on their back. Both accidental forms are known to create flat spots on the back of the cranium.

Fractures - Depression fractures are most commonly seen in the cranium; bone is pressed inward and may affect any of the three structures of the cranial vault bones.

Gun shot wounds – Circular holes with distinct edges. The entry wound smaller and has a beveled inner table. The exit wound is larger, has beveling of the outer table, and frequently has small fragments associated. Fractures will likely be seen radiating away from the wound, but will end at the cranial sutures. A solid diagnosis would include a use of a radiograph that should show small fragments of metal embedded in the bone (Aufderheide and Rodriguez-Martin 1998).

Trephination – Early form of cranial surgery. Purpose is unknown, but speculation includes decreasing cranial pressure and allowing detrimental spirits to escape. Two forms are common, scraping and cutting. Users of the scraping method employ a sharp surface and scrape across the cranium until a hole is made. A sharp tool is also employed in the cutting method, however instead of scraping the individual will make linear cuts creating a square fragment of bone that is popped out after perforating the full thickness of the bone. In either method, it is necessary to not penetrate too deeply to protect the dura which aids in holding infection at bay.

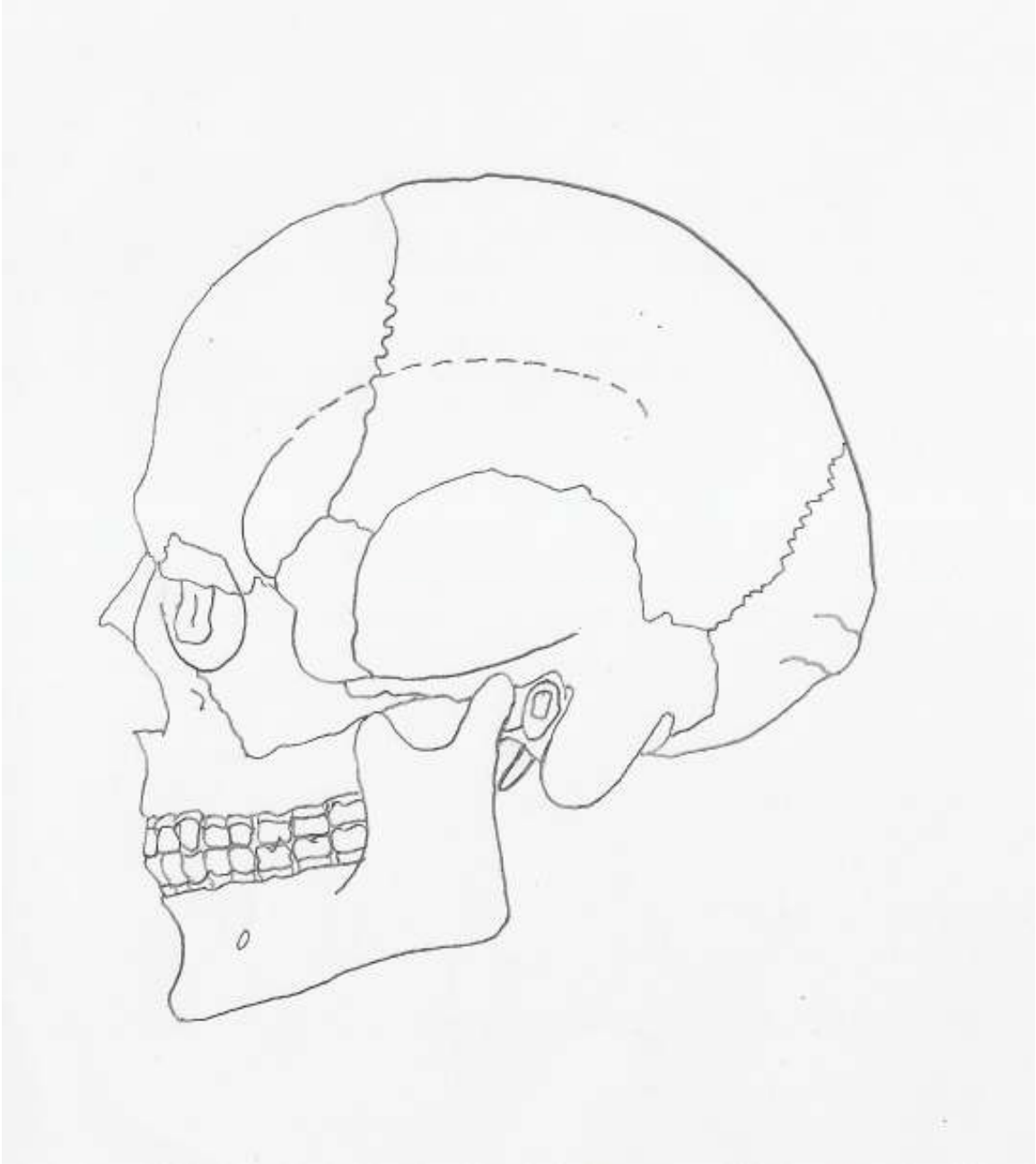
Cut marks – Sharp weapons will leave sharply defined margins, and may be observed as elongated v-shaped marks (Aufderheide and Rodriguez-Martin 1998). It is important to note that cut marks occur during excavation and also in the lab during observation. These accidental marks can be differentiated from antemortem/perimortem cut marks on the basis of color. Accidental marks will be lighter in color than the surrounding bone, while the antemortem/perimortem marks will be the same color as the surrounding bone.

Cranial Pathology

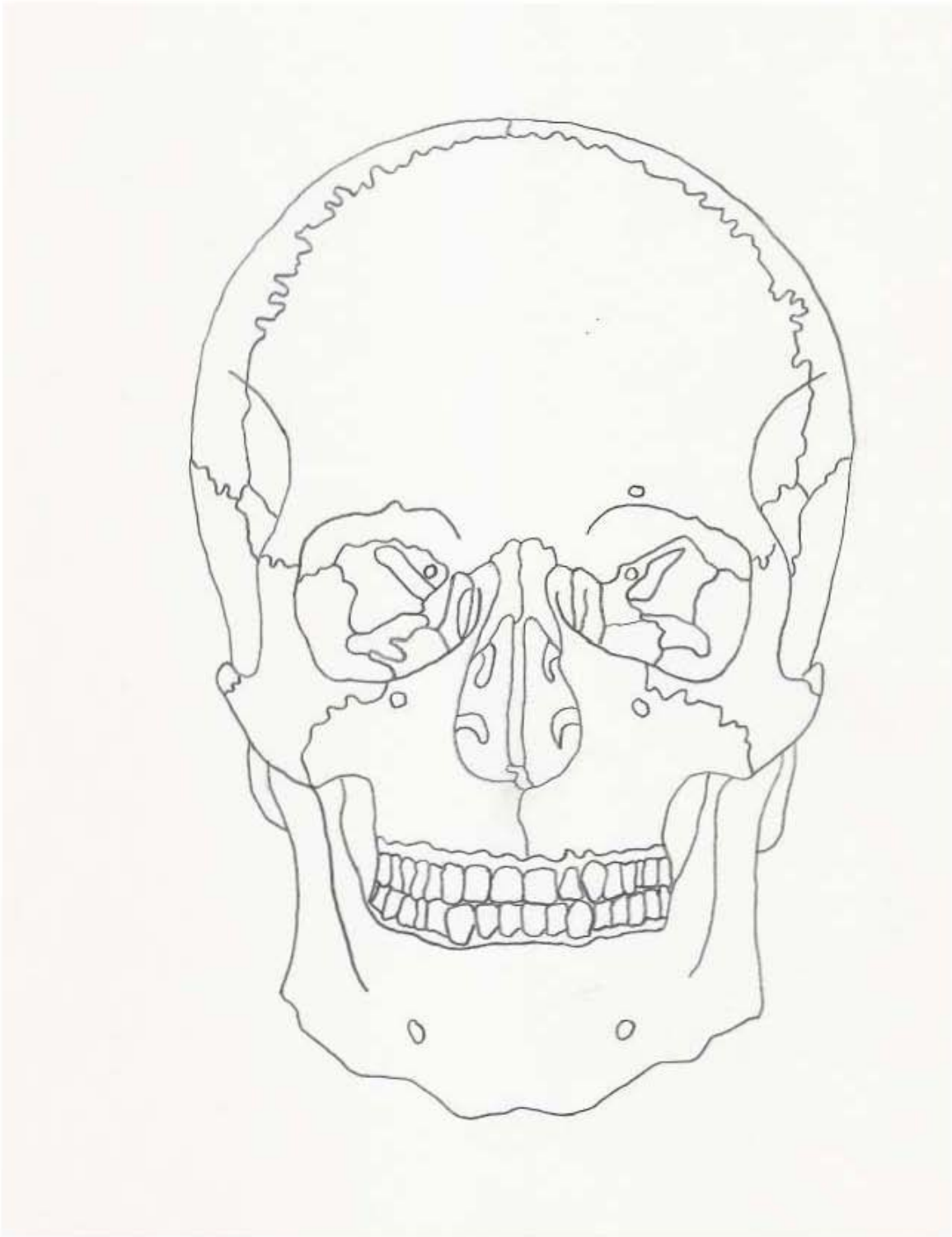
Cribria Orbitalia – Appears on the roofs of the orbits as an increase in porosity or expansion of the diploe into the orbital cavity. *Cribria Orbitalia* is thought to be a general indicator of anemia, although the cause could be a variety of things including malnutrition, parasites, or other physiological illness.

Porotic Hyperostosis – May appear ectocranially as increased porosity with an associated thickening of the bone. Can only be confirmed through radiography; a “hair-on-end” appearance of the diploe. *Porotic Hyperostosis* is thought to be a general indicator of anemia, although the cause could be a variety of things including malnutrition, parasites, or other physiological illness.

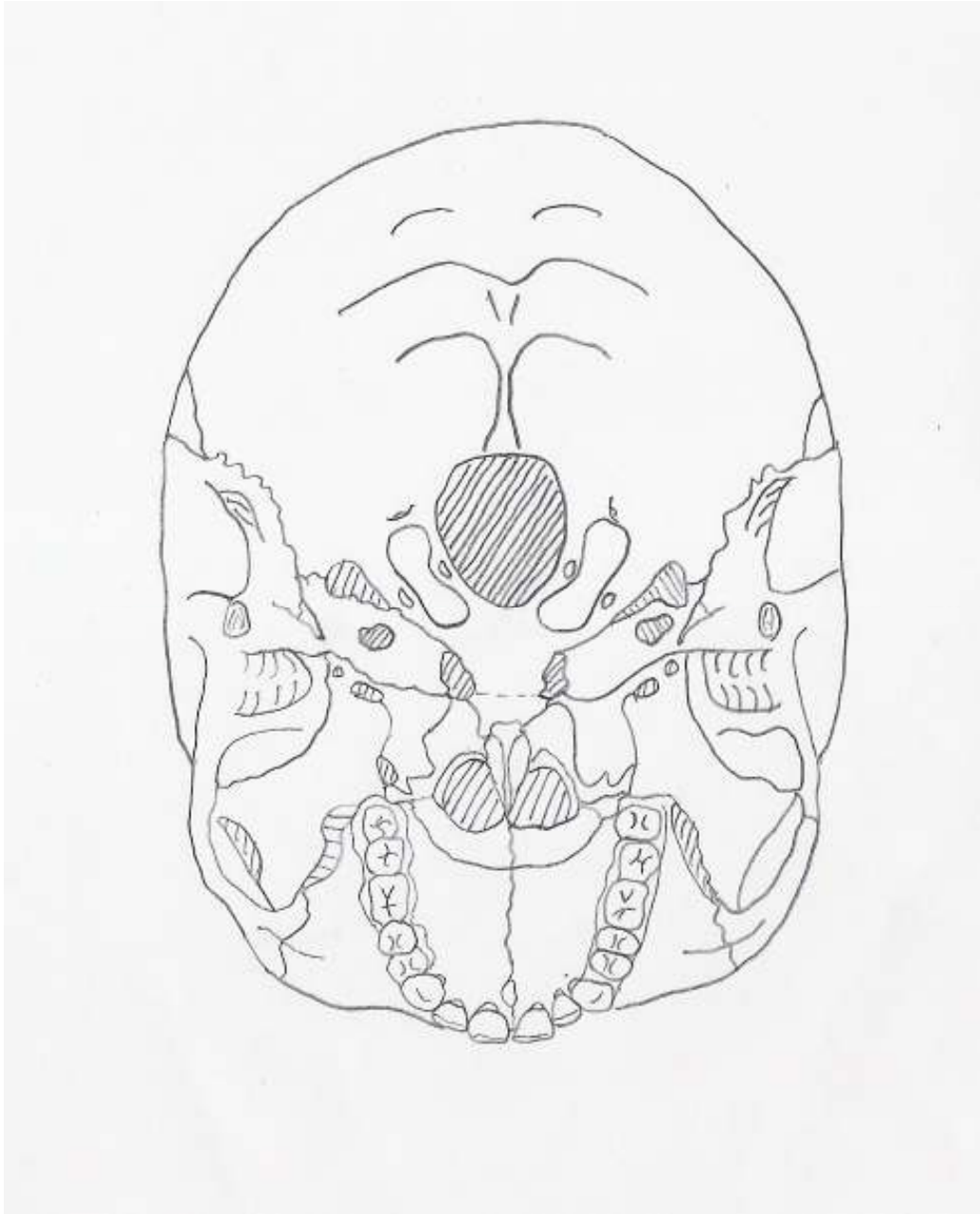
Craniosynostoses - Early closure of the cranial vault sutures. Depending on the suture that fuses early, the shape of the cranium will become distorted.




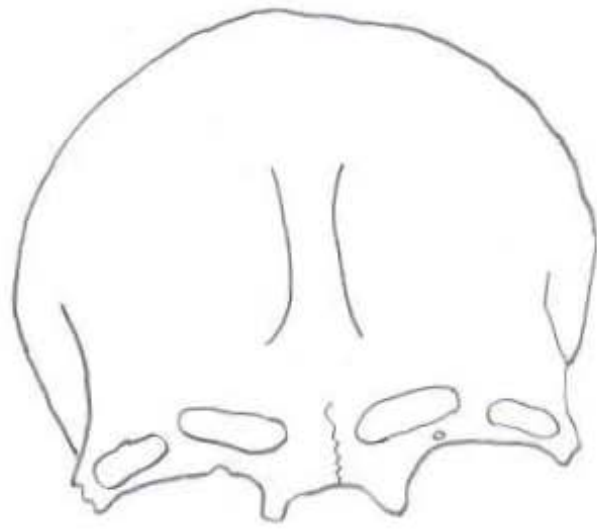
Lateral view of the skull.



Frontal view of the skull.

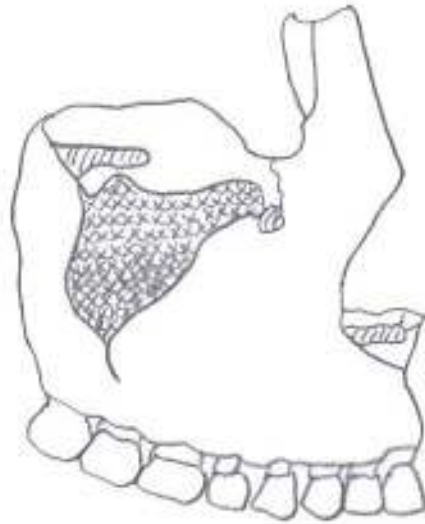


Inferior view of the skull.

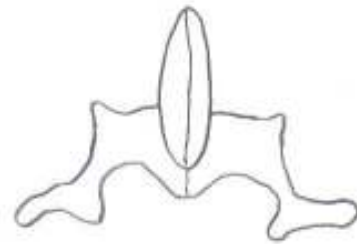
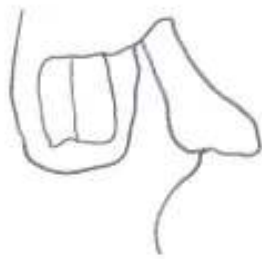


Top – frontal bone.

Bottom – parietal bone.

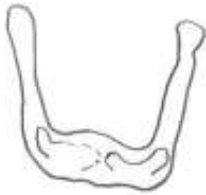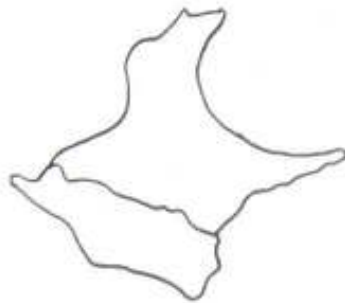

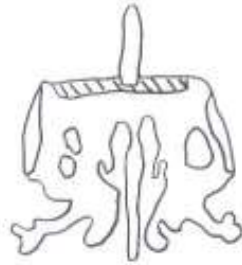
Top – maxillary bone.

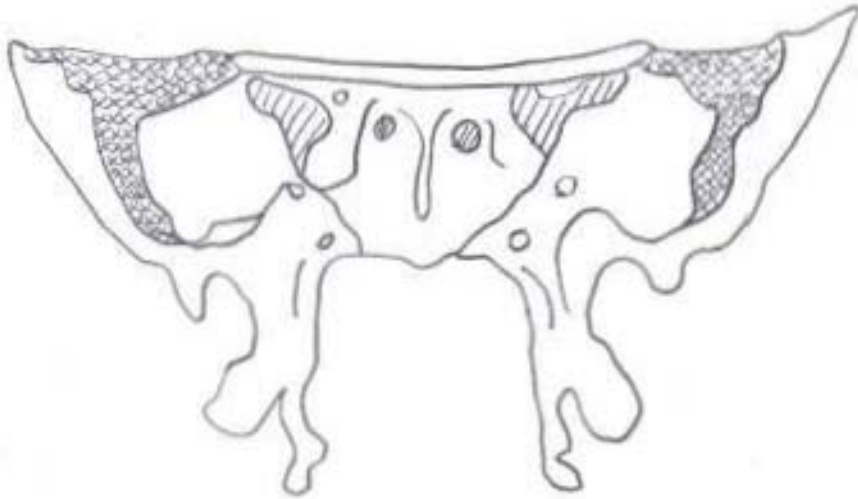
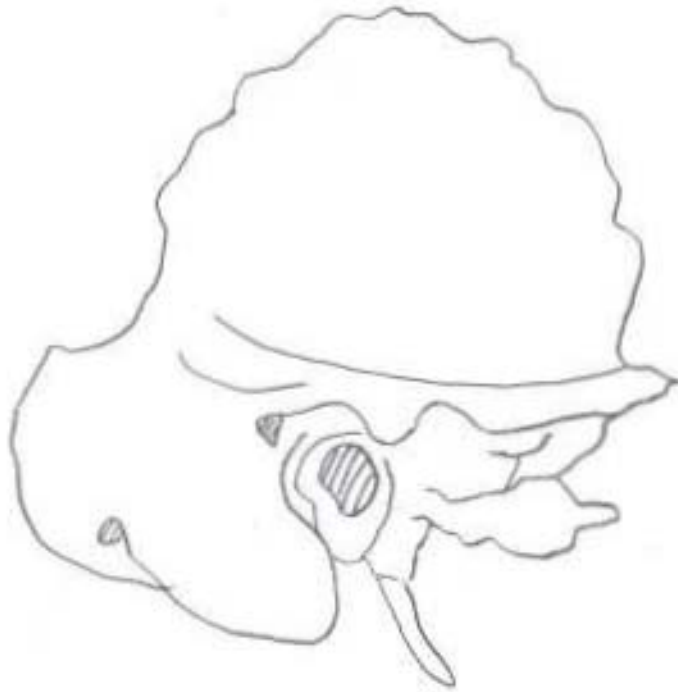

Bottom left – lacrimal bone.

Bottom right – palatine bone.

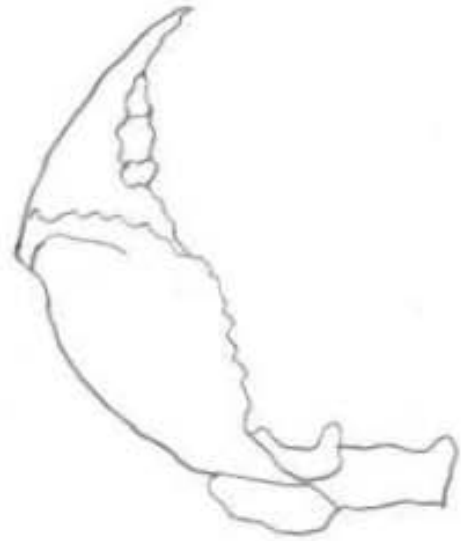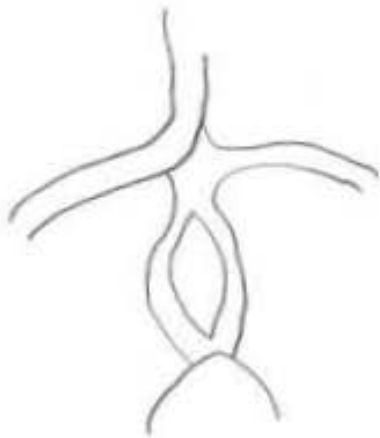
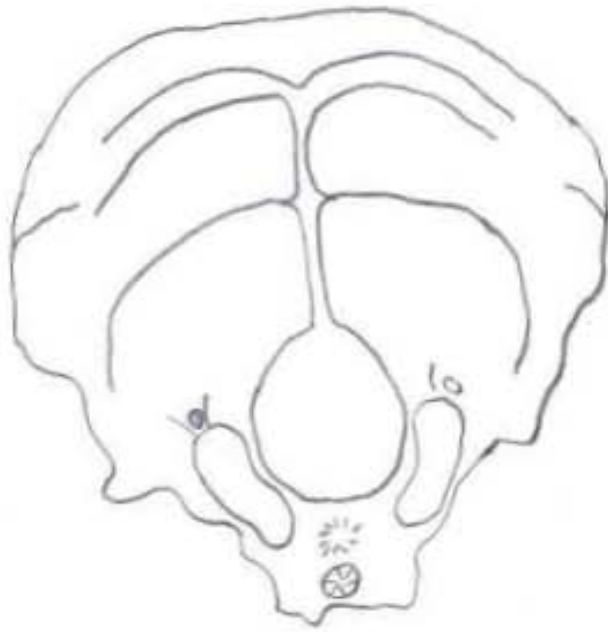


Top – ethmoid. Middle – zygomatic.
Bottom Left – hyoid. Bottom Right – vomer.

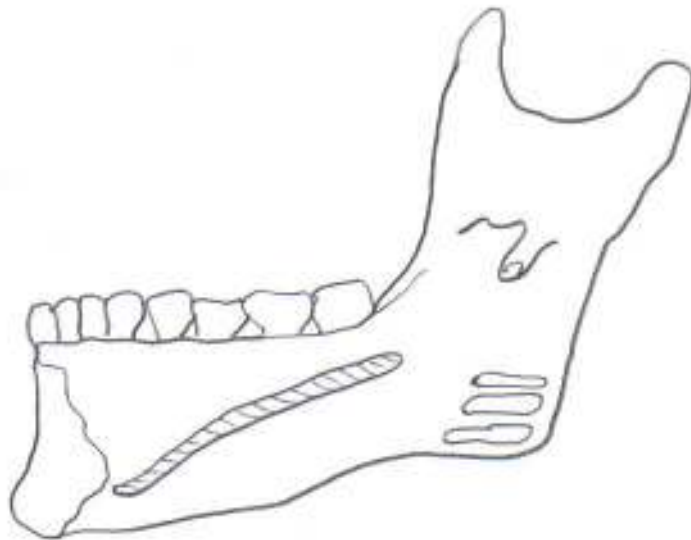
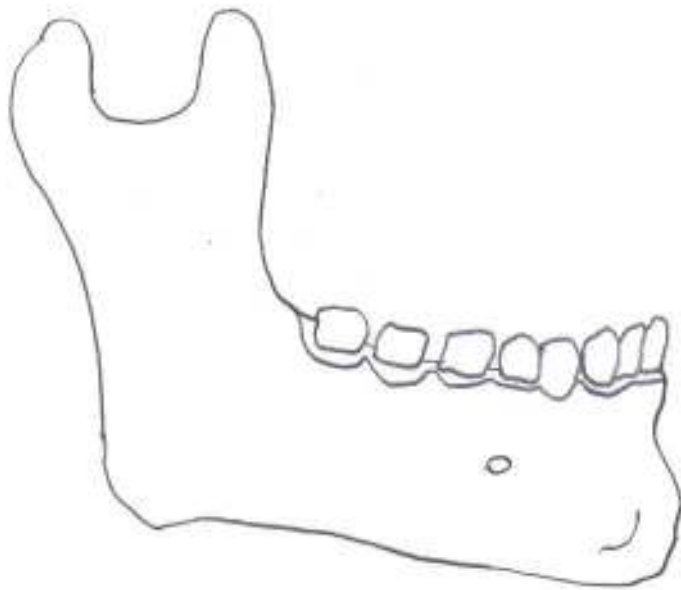


Top – temporal bone.

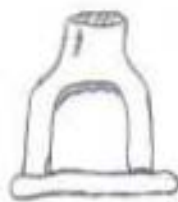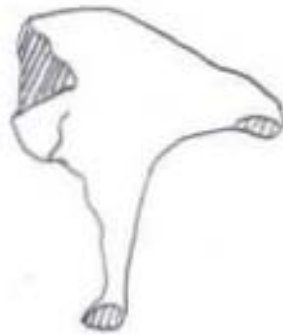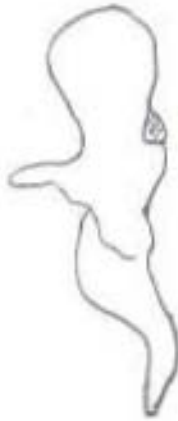Bottom – sphenoid bone.



Occipital Bone



Mandible



Top – Malleus. Middle – Incus. Bottom – Stapes.

Post-Cranial Bones

Locate and identify the features noted below for the post-cranial bones. Pay particular attention to the morphology of the epiphyses as these can be used in distinguishing side in complete and fragmentary remains.

Humerus

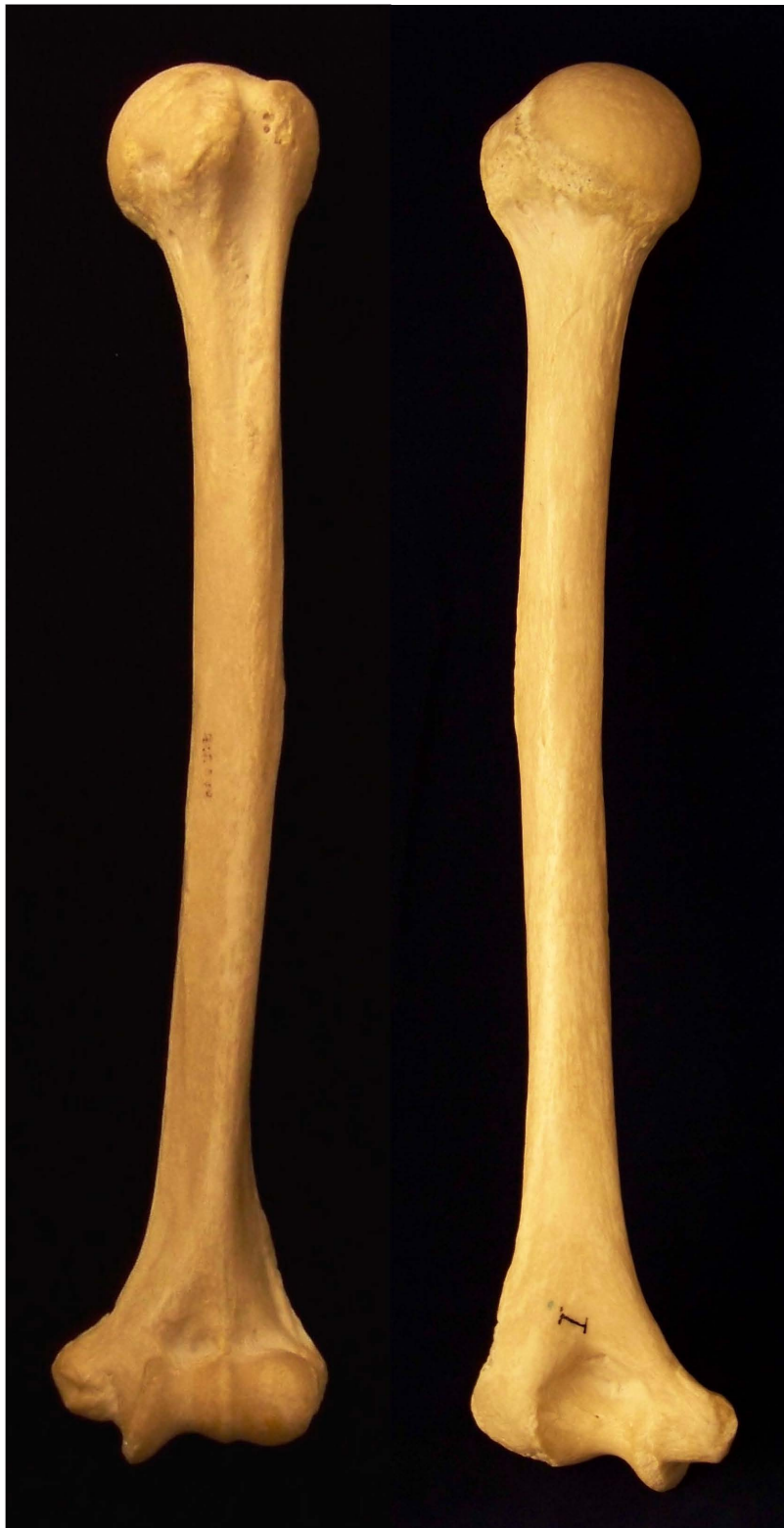Head
Neck
Greater and lesser tubercles
Shaft
Trochlea
Coronoid fossa
Olecranon fossa
Lateral and medial epicondyles
Capitulum
Intertubercular or bicipital groove
Deltoid tuberosity
Surgical neck

Ulna

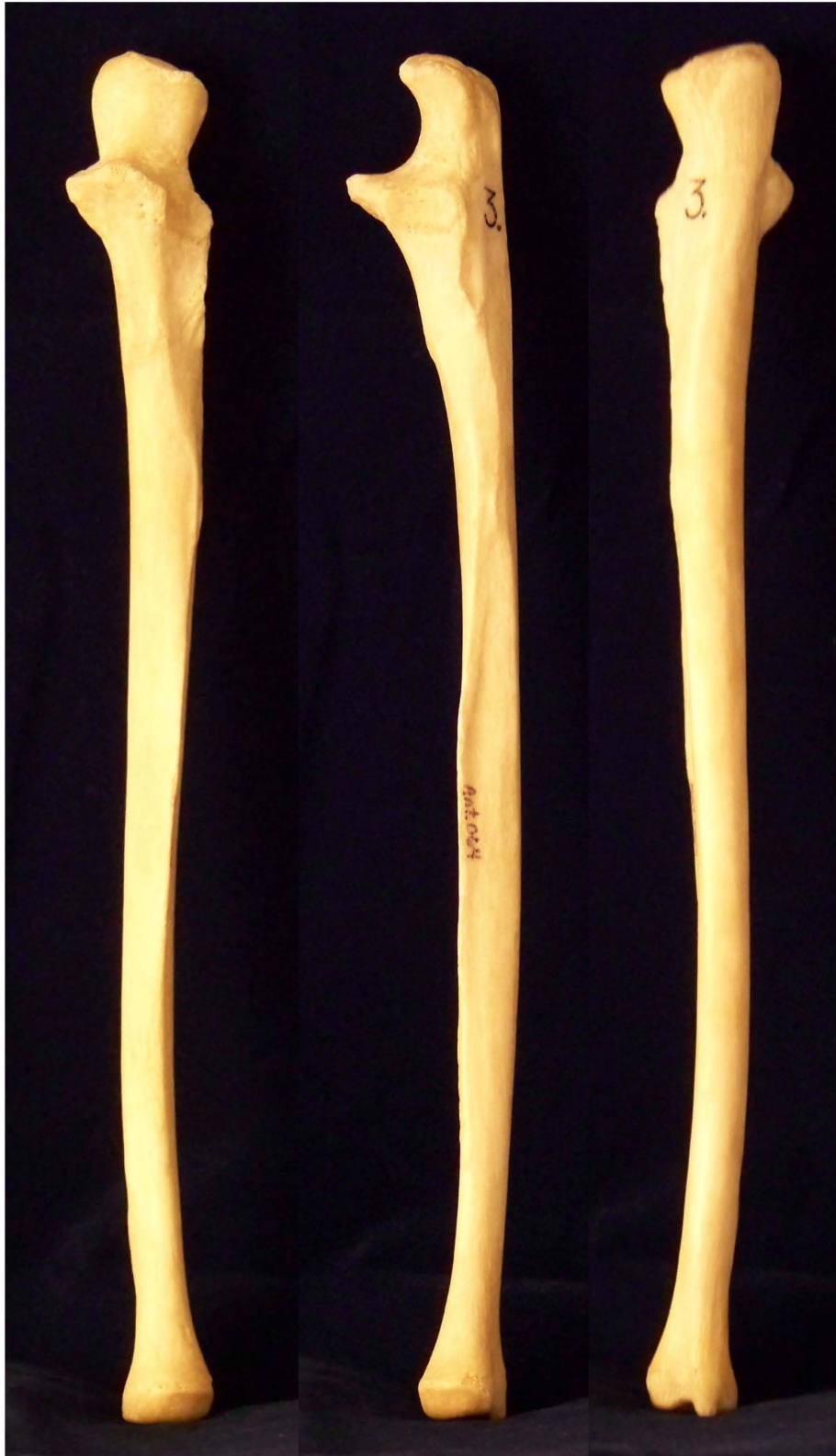Olecranon process
Trochlear or semi-lunar notch
Radial notch
Coronoid process
Shaft
Head
Styloid process

Radius

Head
Neck
Radial tuberosity
Shaft
Styloid process
Ulnar notch
Dorsal tubercles



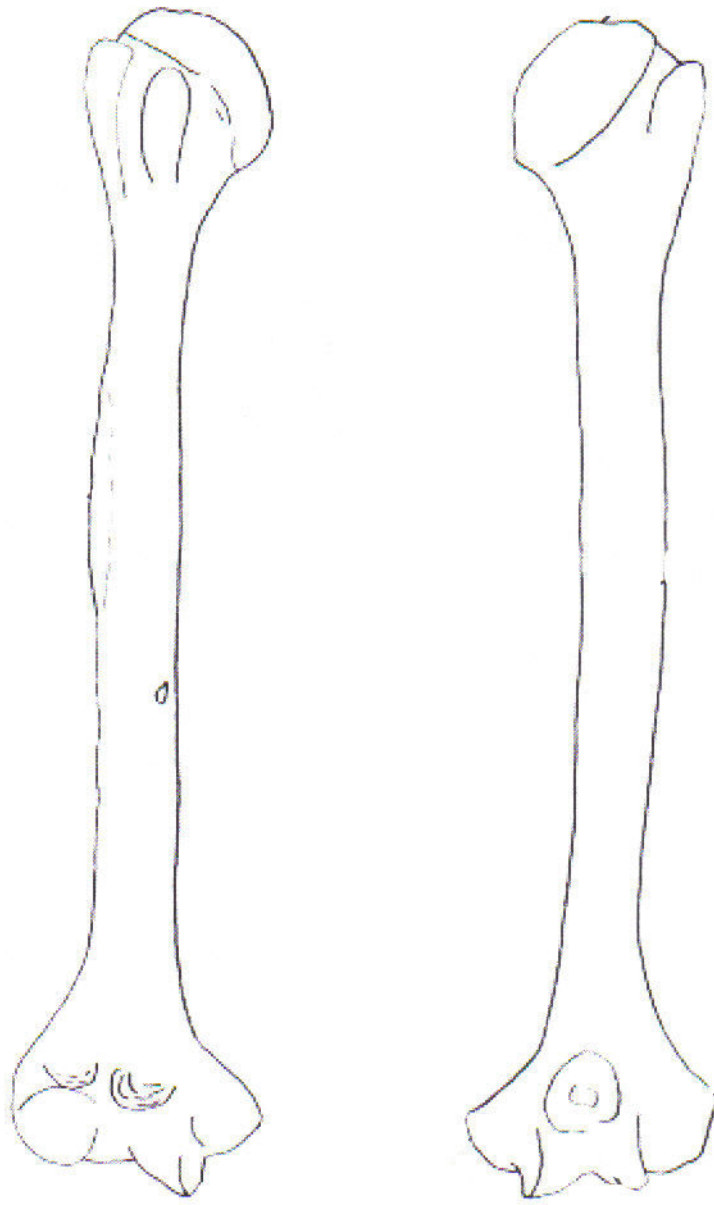
Humerus. Left anterior and right posterior.





Ulna. Left anterior, center lateral, and right posterior.



Radius. Left anterior and right posterior.



Humerus



Left – radius. Right – ulna.

Femur

Head

Neck

Greater and Lesser Trochanters

Linea Aspera

Lateral and medial condyles

Intercondyloid fossa

Shaft

Lateral and medial epicondyles

Fovea capitis femoris

Fibula

Styloid process

Shaft

Lateral malleolus

Malleolar fossa

Patella

Medial facet (smaller)

Lateral facet (larger)

Base

Apex

Tibia

Medial and lateral condyles

Tibial tuberosity

Shaft

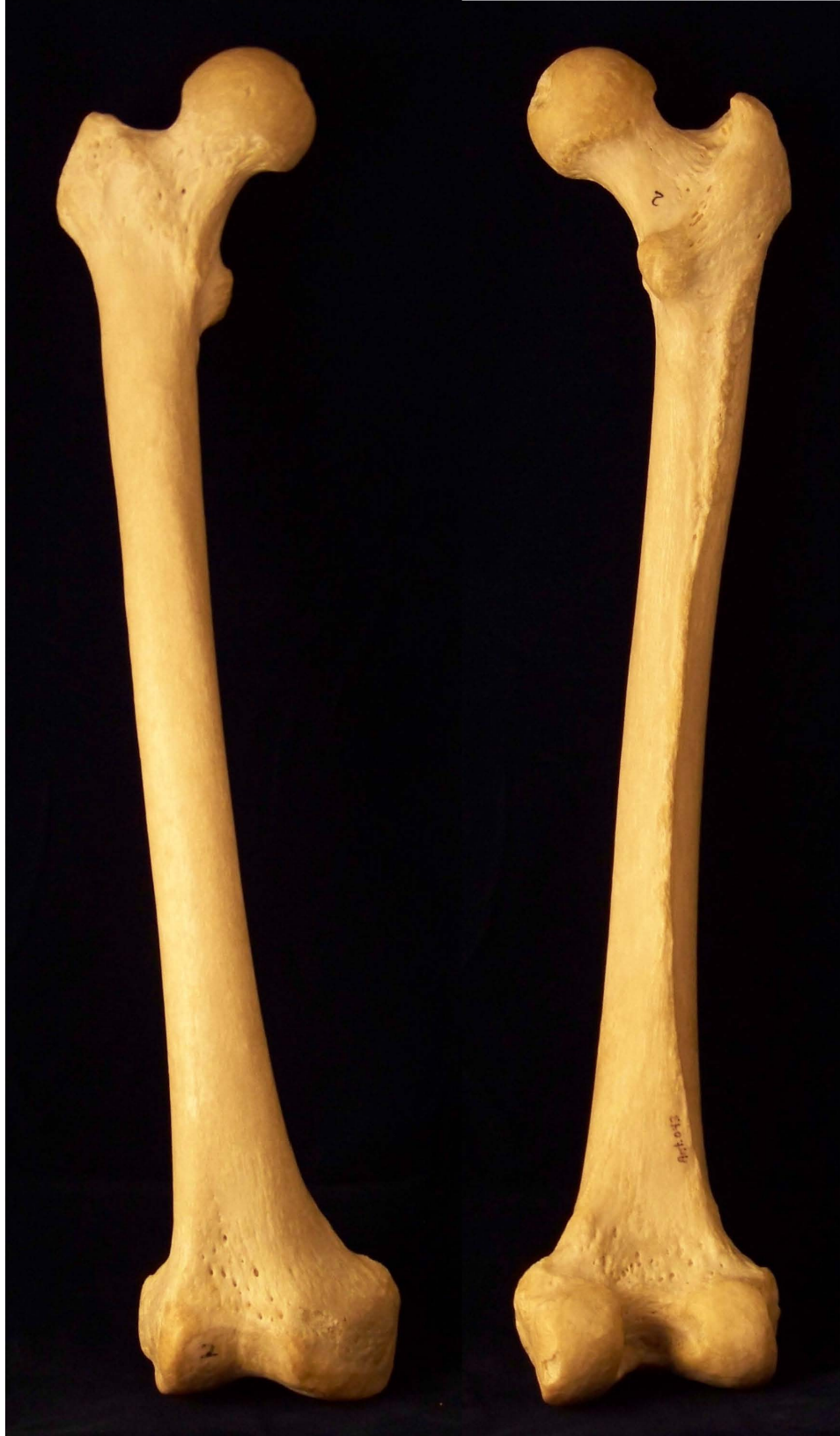Anterior crest

Medial malleolous

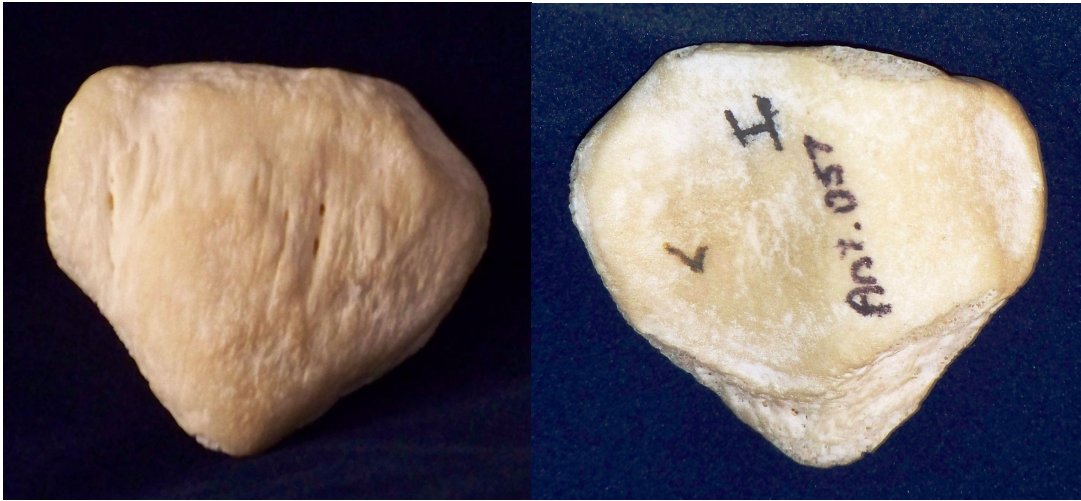Interosseous crest

Popliteal lines

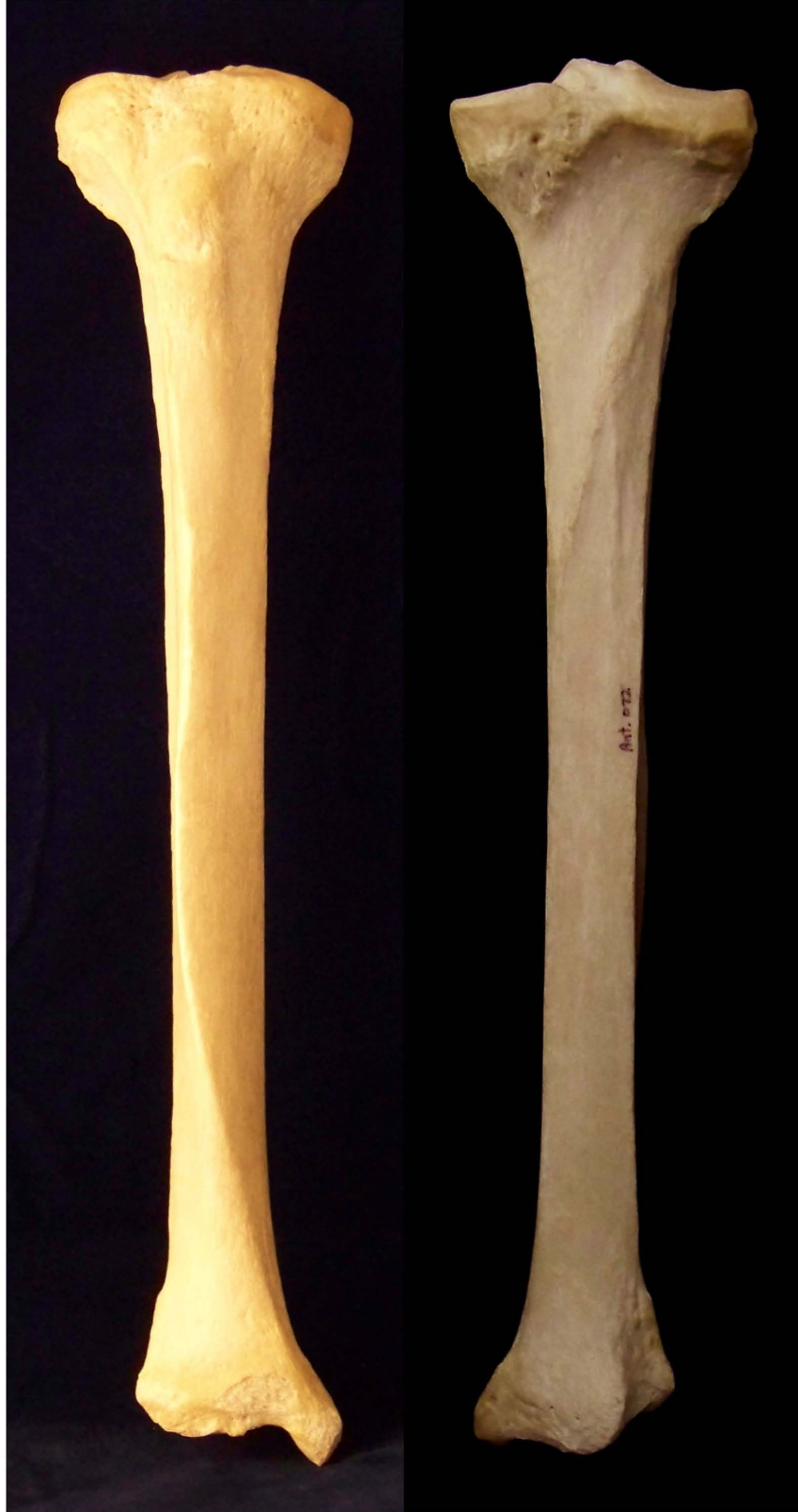Intercondyloid tubercles and fossa



Femur. Left anterior and right posterior.



Patella. Left anterior and right posterior.



Tibia. Left anterior and right posterior.



Fibula, left anterior and right posterior.

Non-Metric Traits of the Appendages

Bipartite patella

Division of the patella at the insertion site for the vastus lateralis muscle. Similar to the vastus notch, but has an accessory bone present. The area of division will be porous, centrally roughened, and smooth margins. Seen at a higher frequency among males.

Septal aperture

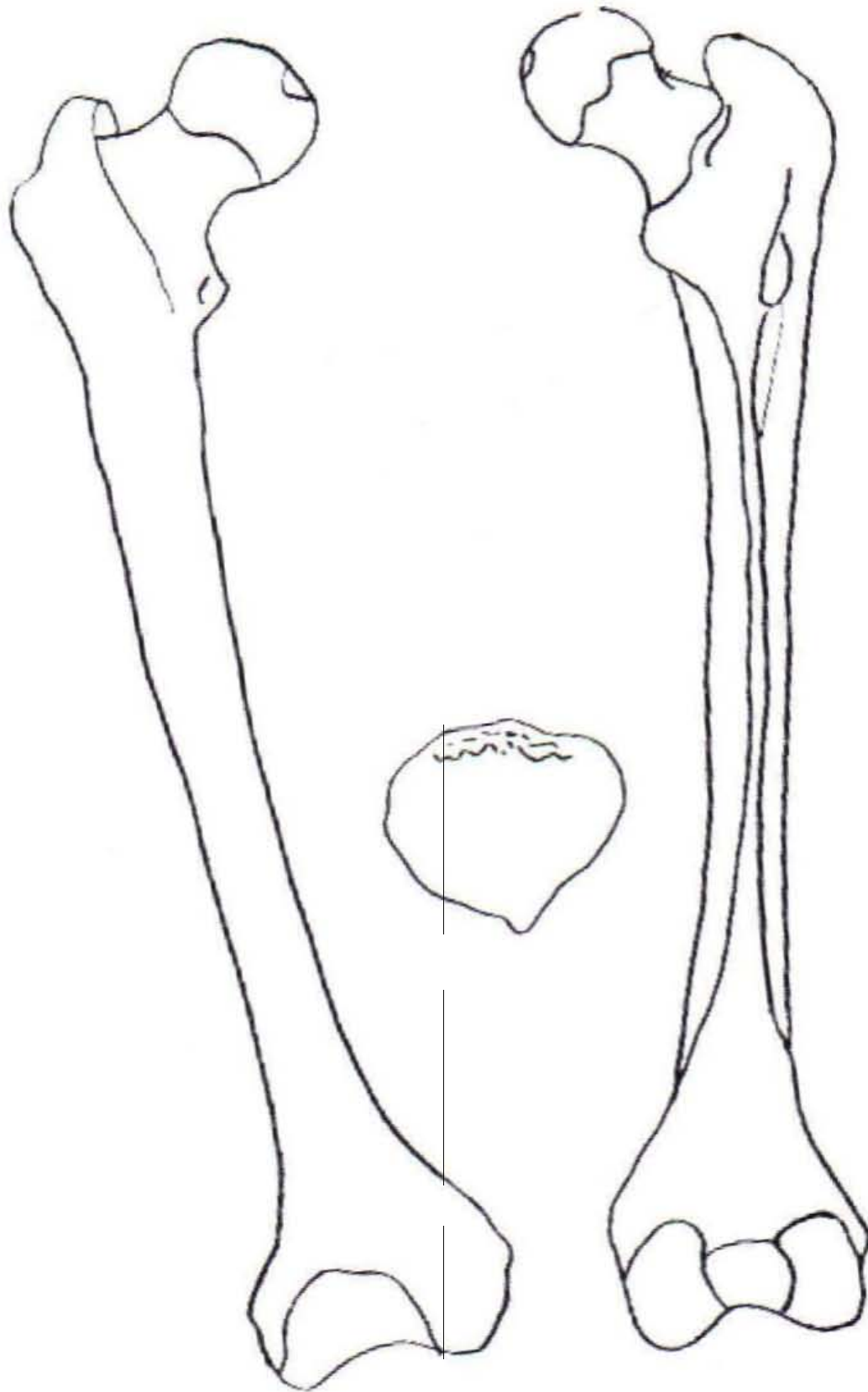
Perforation of the olecranon process, may be large or small. Seen at a slightly higher frequency among females.

Supratrochlear spine

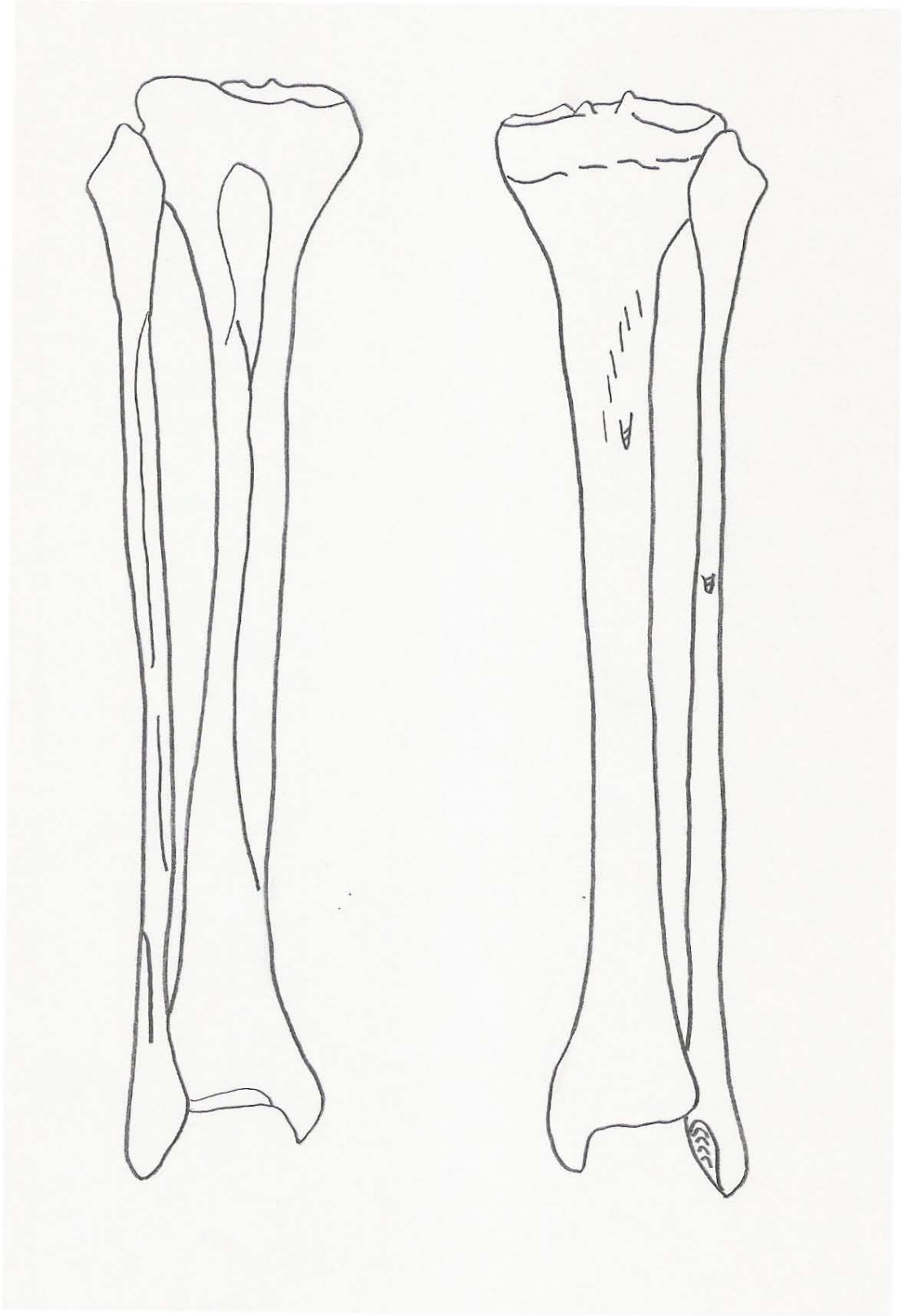
Bony projection at the attachment site for the pronator teres muscle on the inferior portion of the anterior aspect of the humeral shaft.

Vastus Notch

Division of the patella at the insertion site for the vastus lateralis muscle. The notch area is smooth, flat, and lacking in porosity.



Femur and Patella



Tibia (medial) and Fibula (lateral)

Bones of the Hand

Eight carpal bones, in two rows, make up the bones of each wrist. The articular surface formed by the proximal row is convex and articulates with the distal end of the radius. The ulna takes no direct part in the wrist joint. Observe that the palmar side of the carpals are arched so as to form a tunnel through which pass the tendons and muscles of the forearm responsible for flexion of the fingers. The extensor tendons similarly lie on the back of the wrist, less protected. The majority of the movements of the hand, with the major exception of the opposition of the thumb, are brought about by muscles which lie in the forearm; some of these muscles originate as high as the epicondyles of the humerus.

The bones of the palm are known as the metacarpals, four of which are bound together by ligaments while the thumb is freely moveable. Those bones making up the fingers are the phalanges. The phalanges closest to the wrist are the proximal, further out medial, and making up the finger tips the distal phalanges.

Notes on Siding*

Navicular/Scaphoid – Concave surface toward you with the tubercle pointing superiorly; the bone belongs to the side to which the tubercle points.

Lunate – Place the flat surface down, concave surface facing you, the remaining facet will rise upward toward the side from which it comes.

Triquetral – Between your fingers, place the two facets that come together. The bone should be vertical with the largest facet toward you. The remaining facet will point toward the side from which it comes.

Pisiform – With the non-articular surface pointing superiorly and the facet facing you, a groove will be located on the side from which the bone comes.

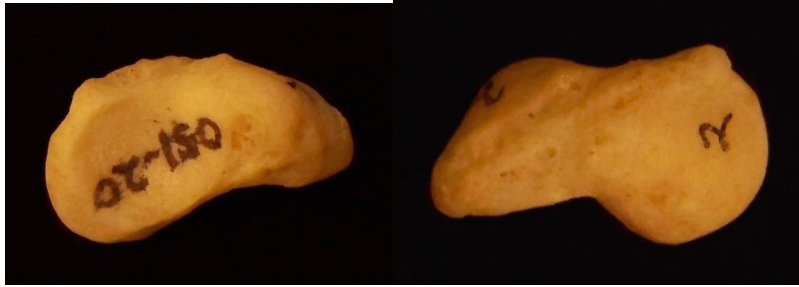
Greater Multangular – Lay the bone on the table with the tubercle pointing superiorly and away from you, with the concave surfaces lateral and there will be a groove next to the tubercle on the side from which the bone comes.

Lesser Multangular – This bone has a boot shape in appearance. Take the boot and put the sole on the table, with the v-shaped toe pointing toward you. The toe of the boot points toward the side from which it comes.

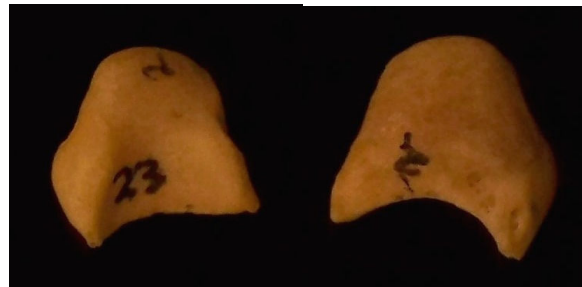
Capitate – The head should be placed superiorly and the long narrow articulation toward you, the bone belongs to the side on which the long narrow articulation is observed.

Hamate – The hook and facets should be positioned away from you, with the flat surface down and the hook will lean toward the side from which it comes.

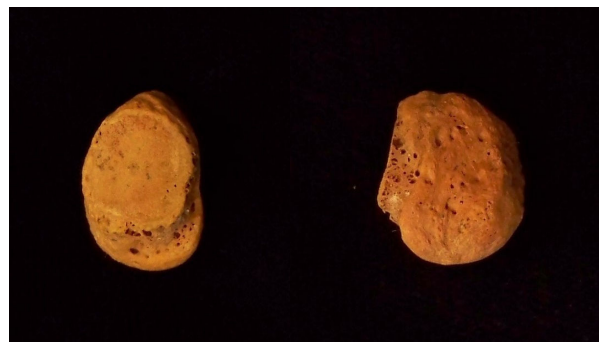*Siding of the hands after White 2000.



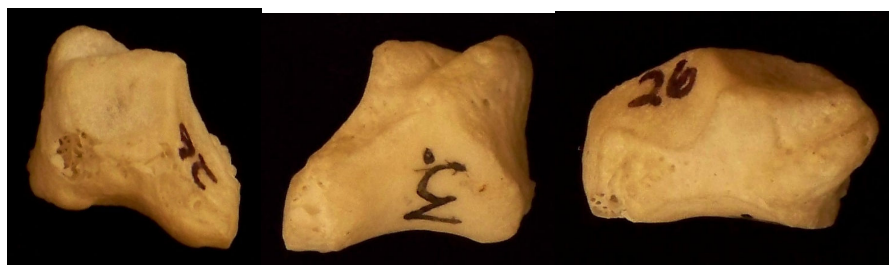Navicular. Right side. Left view from capitate and right radial articulation.



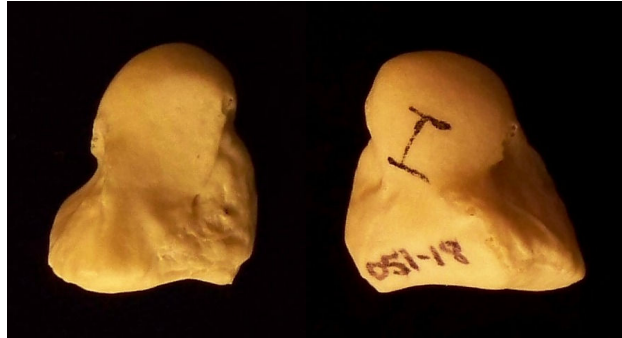Lunate. Right side. Left view from the capitate and non-articular view.



Pisiform. Right side. Left view from triquetral and left palmar view.



Greater Multangular or Trapezium. Right side.



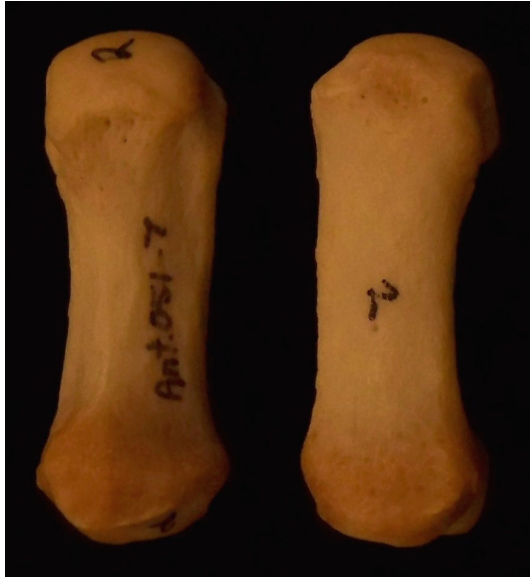Capitate. Left side. Left view from the hamate and right view from the scaphoid and trapezoid.



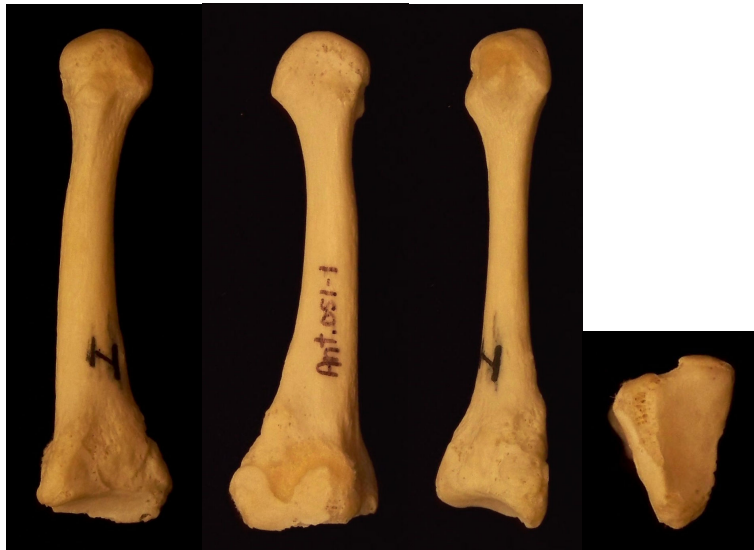
Hamate. Right side. Left view from triquetral, middle left view from the fourth and fifth metacarpal bases, middle right view from the capitate.



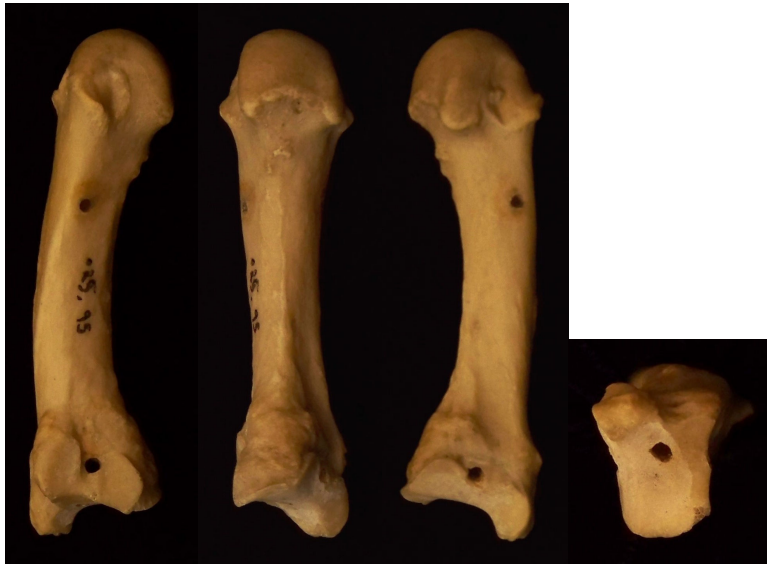
Triquetral. Left side. Middle view from the triquetral.



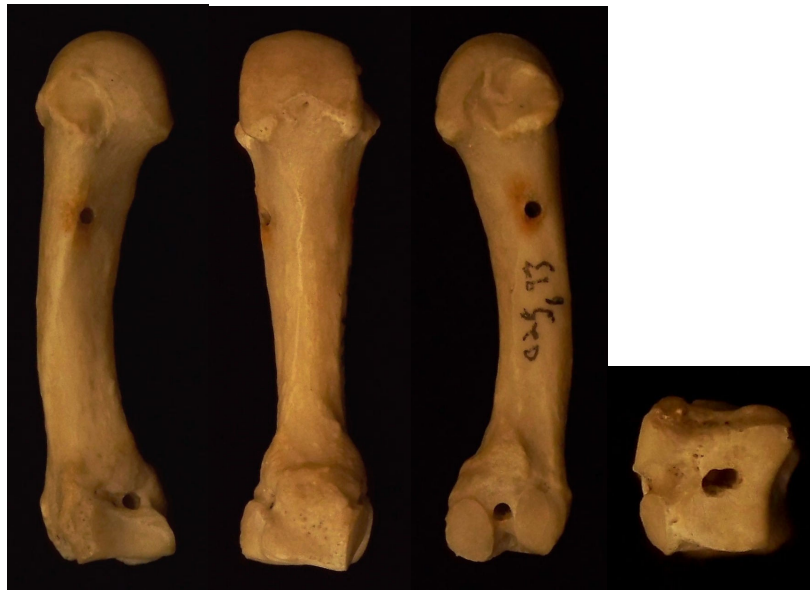
Metacarpal 1. Right side. Left palmar and right dorsal.



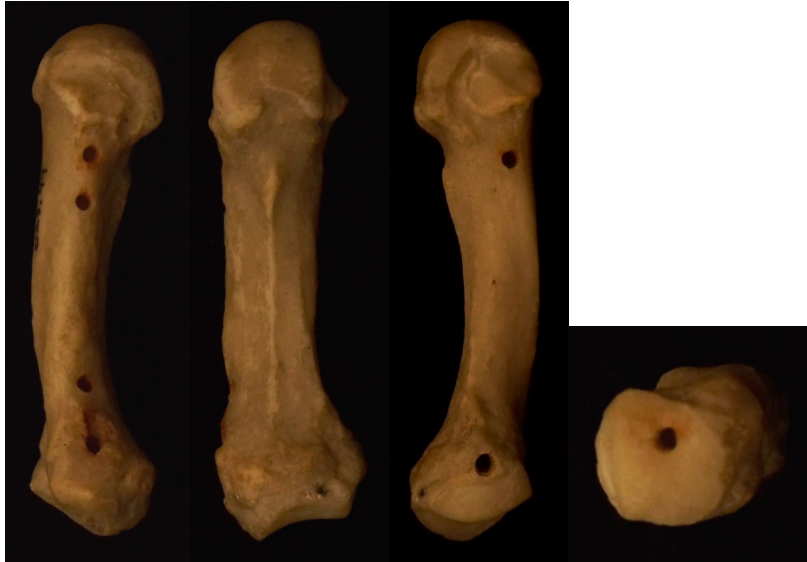Metacarpal 2. Left side. Left medial, middle left lateral, middle right dorsal, right proximal base.



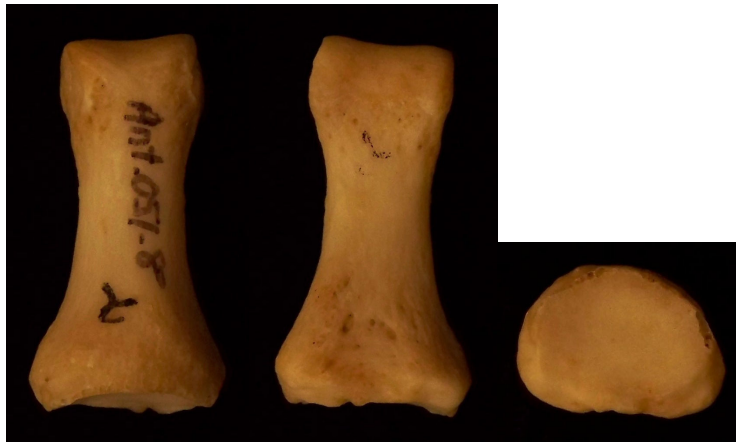
Metacarpal 3. Right side. Left medial, middle left palmar, middle right lateral, right proximal base.



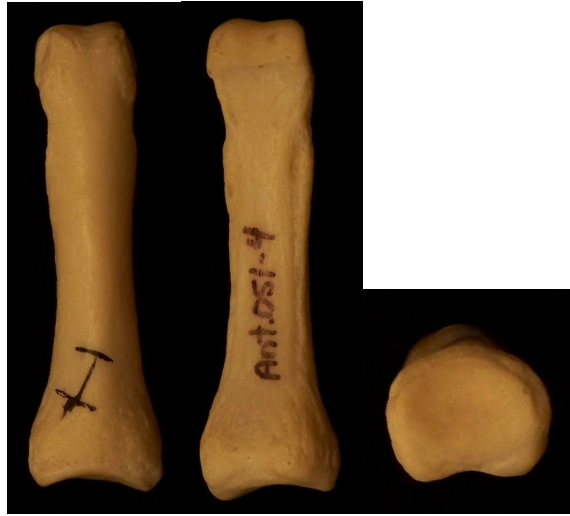Metacarpal 4. Right side. Left medial, middle left palmar, middle right lateral, right proximal base.



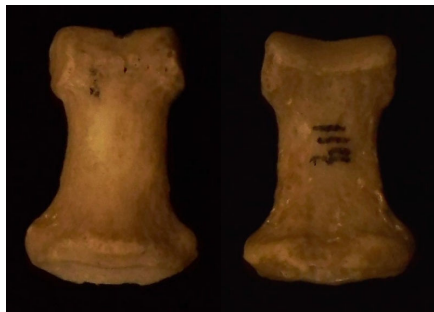Metacarpal 5. Right side. Left medial, middle left palmar, middle right lateral, right proximal base.



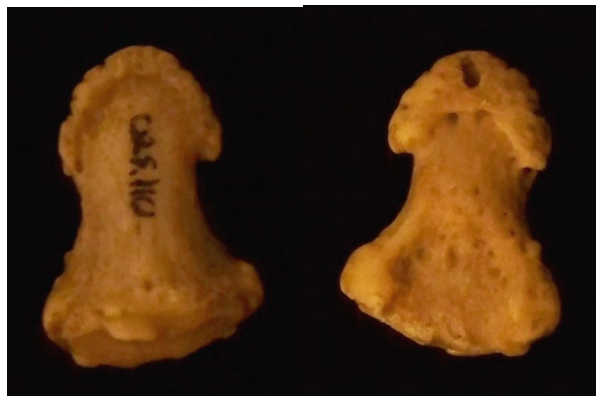First Proximal Phalange of the Hand. Left dorsal, middle palmar, right proximal base.



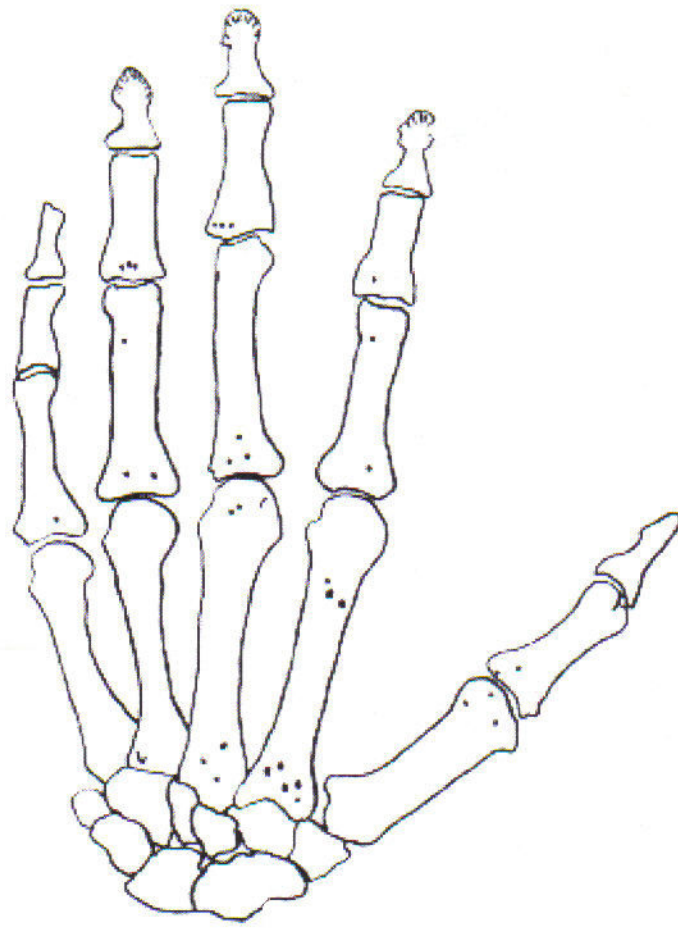
Proximal Non-First Phalanges of the Hand. Left dorsal, middle palmar, right proximal base.



Medial Phalanges of the Hand. Left dorsal and right palmar.



First Distal Phalange of the Hand. Left dorsal and right palmar.



Hand

Bones of the Feet

The tarsus or posterior portion of the foot is comprised of seven individual bones. A part of the ankle joint is formed by the talus: articulating superiorly and medially with the tibia, laterally with the fibula, inferiorly with the calcaneus, and distally with the navicular bone. The calcaneus or heel is the largest of the tarsal bones, it is located inferiorly and posteriorly in the foot. The other tarsal bones are the cuboid, navicular, and three cuneiform bones. Between the first metatarsal bone and the first cuneiform bone the tarso-metatarsal joint does not allow opposition between the great toe and the remaining digits as in some lower primate forms. In man, the analog in the hand represented by the first carpo-metacarpal joints does permit this unique function.

The middle portion of the foot is made up of the metatarsal bones. The phalanges are the toe bones. Only a proximal and distal phalanx are present in the great toe while the other digits have a middle phalanx as well.

The tarsal bones are much larger than the carpal bones due to their weight bearing requirements. The tarsals and metatarsals form a unit with a limited degree of flexibility. The articulation of the talus and distal epiphysis of the tibia and fibula allow for a strictly hinge-like motion. The most flexible joints within the tarsals are those between the anterior surface of the talus and the navicular, and between the anterior surface of the calcaneus and the cuboid. The motions by which the sole of the foot may be slightly turned medially or laterally, take place at these two joints. Observation of the sole of the articulated foot skeleton will show a considerable concavity between the tuberosity of the calcaneus and the distal ends of the metatarsals. This concavity in life is filled with muscles and any weakening of this arch causes the weight of the body to come to rest on the muscles with painful results. Note the firm articulation between the tarsals and the proximal portions of the metatarsals.

The phalanges of the foot may be readily distinguished from those of the hand by their shortness and roundness of the shaft.

Notes on Siding*

- Calcaneus Place heel posteriorly, sustentaculum tali (projection) is medial. The projection points toward the opposite side from which the bone comes.
- Talus - Place the rounded head anteriorly, the trochlear surface for the tibia is superior, the straightest side is medial, and the angular projecting articulation points laterally. The angular projection points toward the side from which the bone comes.
- Navicular Position the concave surface posteriorly, the convex surface should be anterior with the wide surface superior and the tuberosity medial. The tuberosity points toward the side from which the bone comes.
- Cuboid Hold the large non-articulating surface toward you, the tuberosity points toward the side from which the bone comes.
- Cuneiform I Represents the largest of the cuneiform bones. The large articulating surface is anterior, the sharp ridge superior, and the rough surface without any articulation is medial.
- Cuneiform II Represents the smallest of the cuneiform bones. If the rectangular rough surface without articulations is placed superiorly, the concave triangular facet posteriorly, then the surface with “L” shaped facets is medial.
- Cuneiform III Medium in size compared to the other cuneiform bones. If the rectangular rough surface without articulations is placed superiorly, the triangular articulation posterior (small notch at the apex), then the surface with the two small facets is medial.

*Siding of the hands after White 2000.

Non-Metric Traits of the Feet

Bipartite anterior calcaneal facet

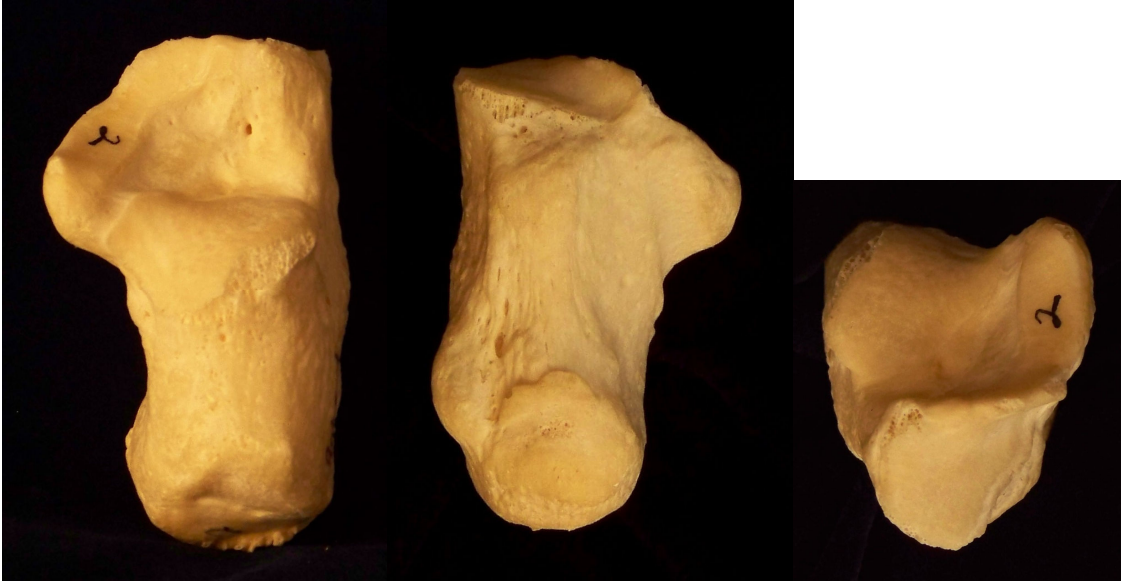
Division of the anterior calcaneal facet.
(Mann and Hunt 2005).

Calcaneus secundarius

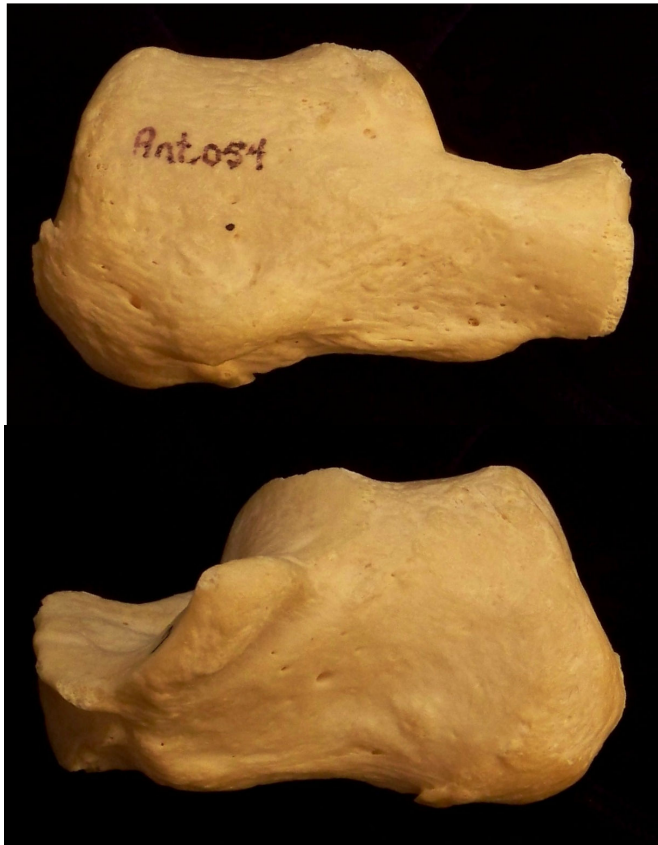
Accessory bone on the anterior aspect of the anterior calcaneal facet. Notch on the calcaneal facet will be porous, centrally roughened, and concave (Mann and Hunt 2005).

Os trigonum

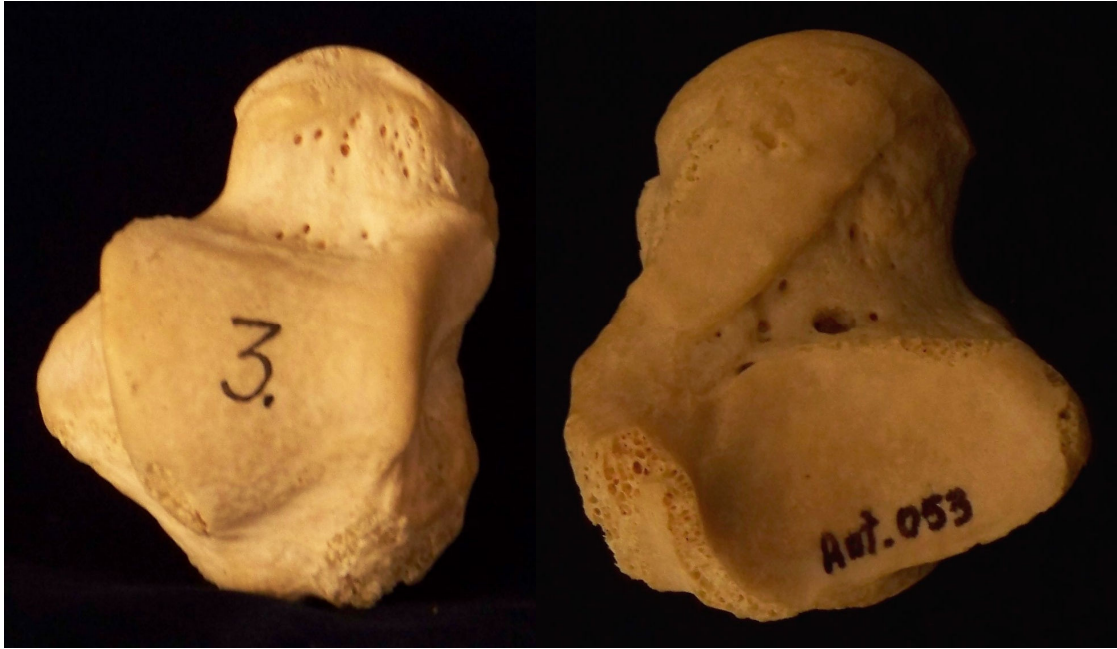Accessory bone in the area of the posterior tubercle of the talus (Mann and Hunt 2005).



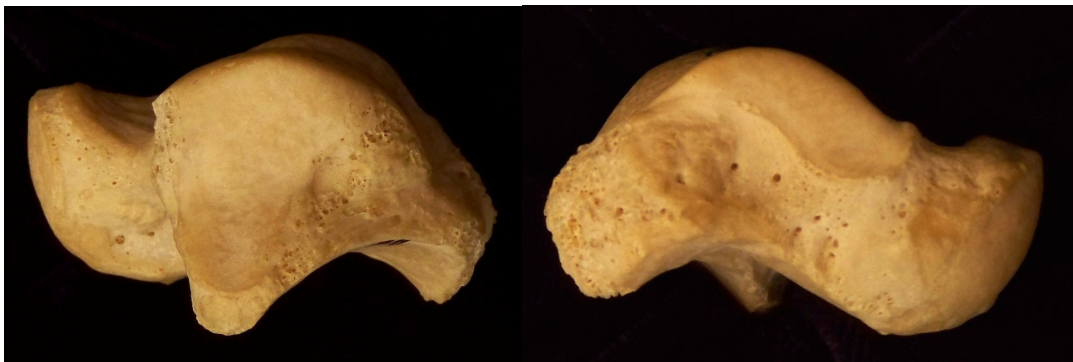
Calcaneus. Right side. Left superior, middle inferior, and right anterior view.



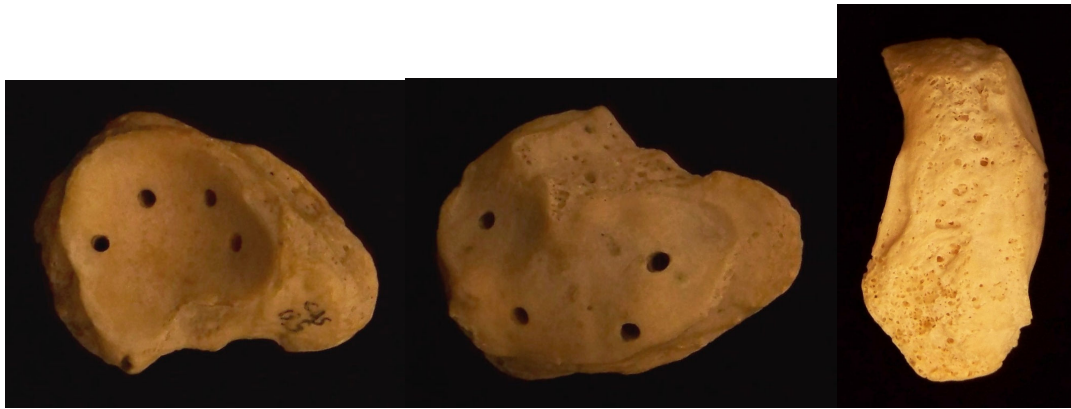
Calcaneus. Right side. Top lateral and bottom medial.



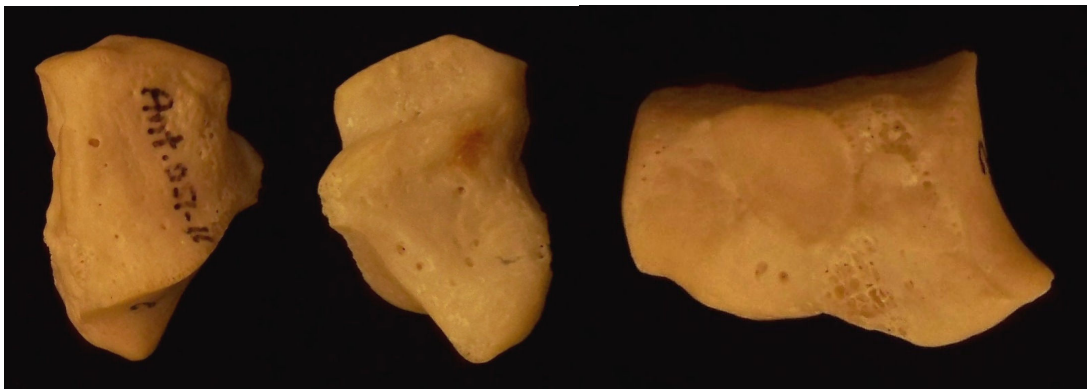Talus. Left side. Left superior and right inferior.



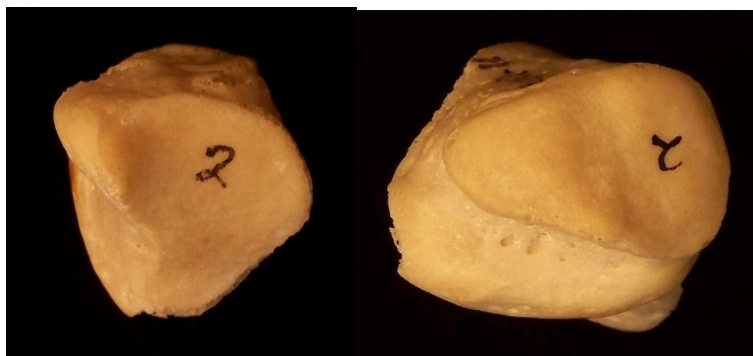Talus. Left side. Left medial and right lateral.



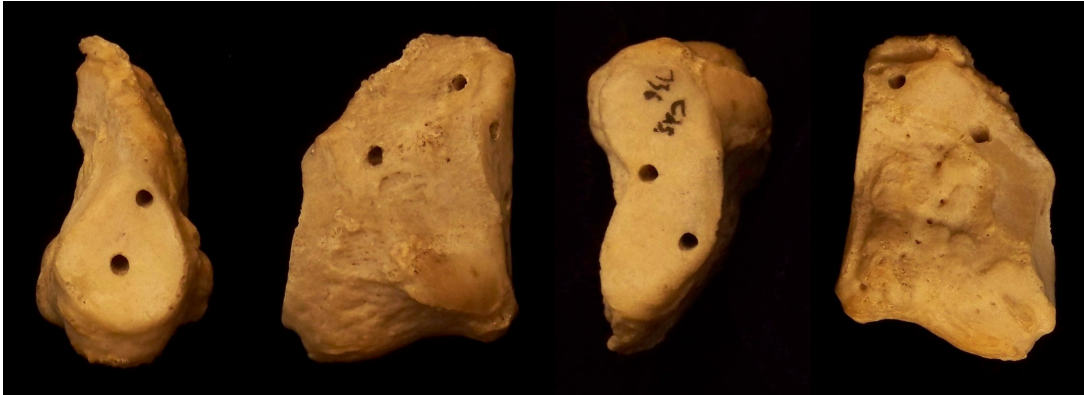Navicular. Left side. Left articular with talus, middle articulation with cuneiforms, and right non-articular view.



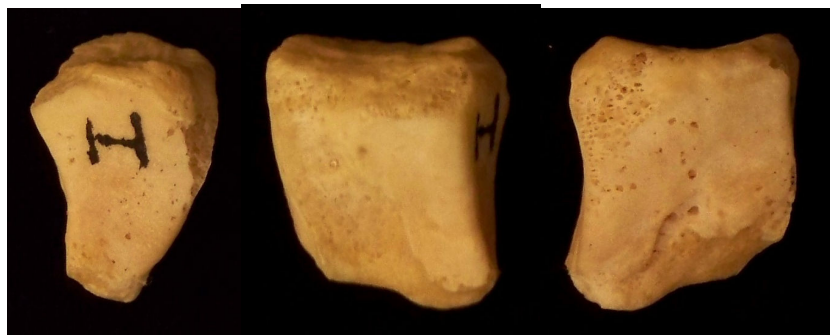Cuboid. Right side. Left non-articular view, middle cuboid tuberosity, right view from the lateral cuneiform.



Cuboid. Right side. Left view from the calcaneus and right view from the 4th and 5th metatarsal bases.



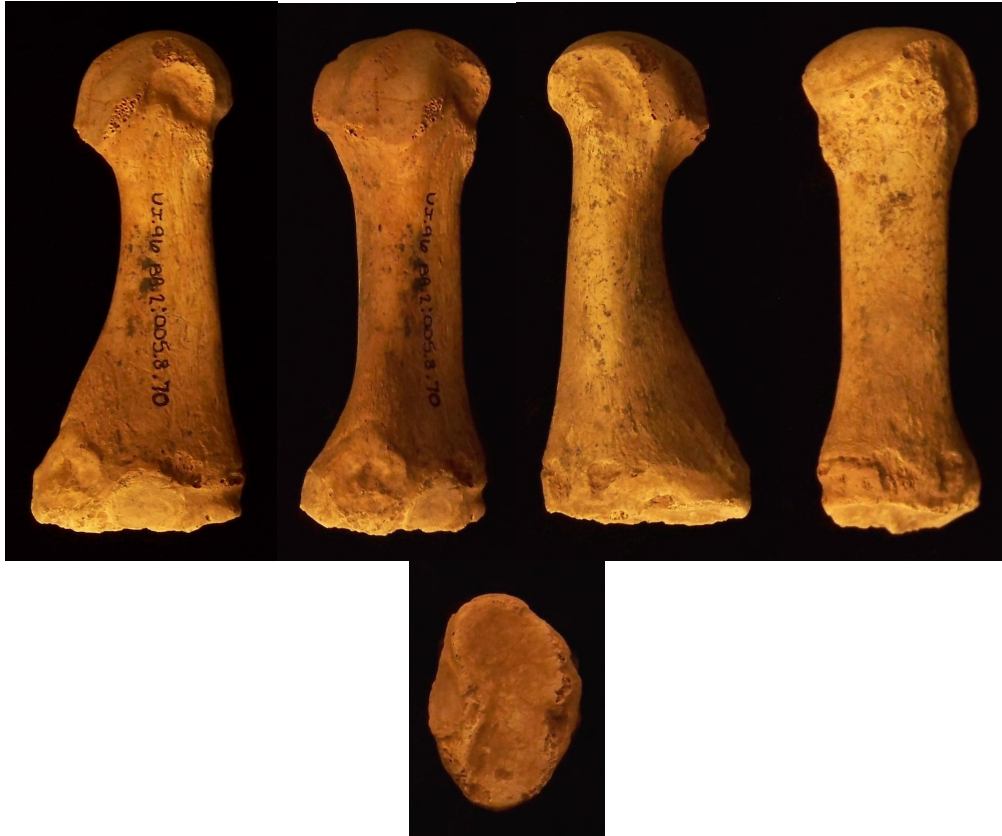
Cuneiform I. Left side. Left view from navicular, middle left medial view, middle right kidney shaped articulation, right view from 2nd cuneiform.



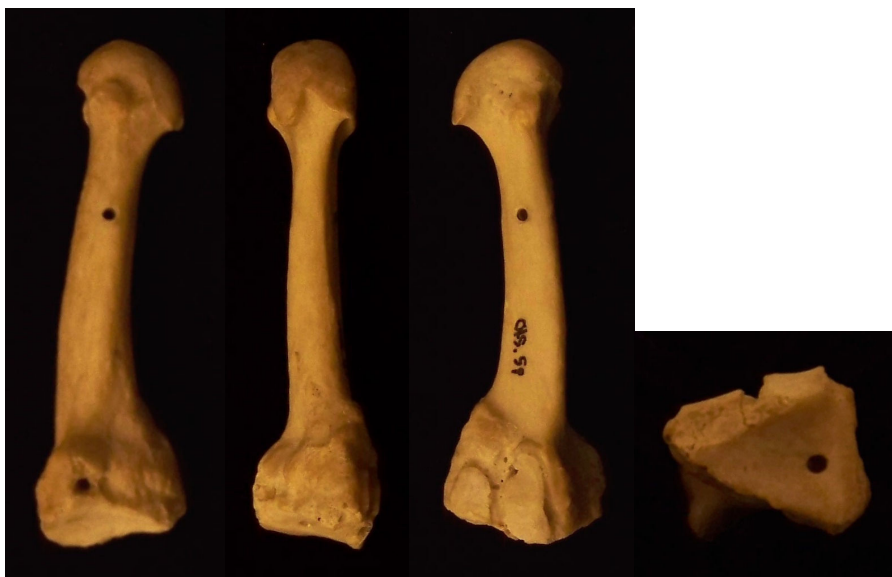Cuneiform II. Left side. Left view from navicular, middle view from 3rd cuneiform, right view from 1st cuneiform.



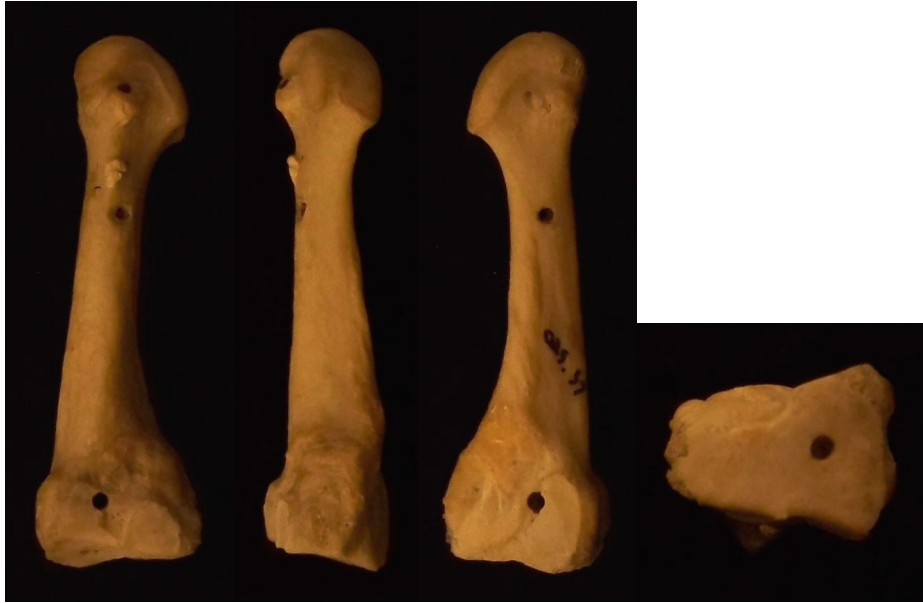
Cuneiform III. Left side. Left view from 2nd cuneiform, middle left Africa shaped articulation, middle right view from navicular, right view from cuboid.



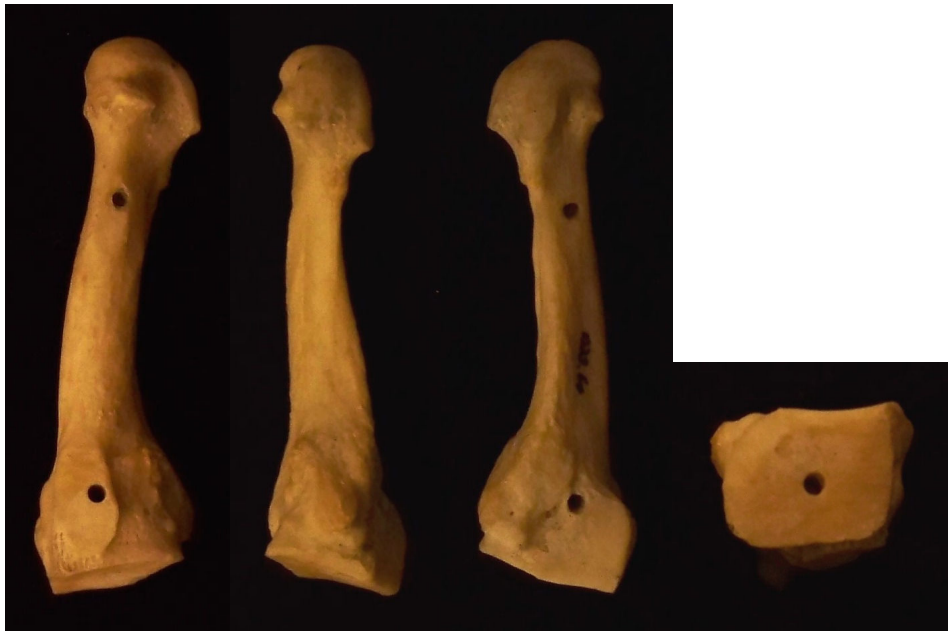
Metatarsal 1. Left side. Left medial, middle left plantar, middle right lateral, right dorsal, bottom proximal base.



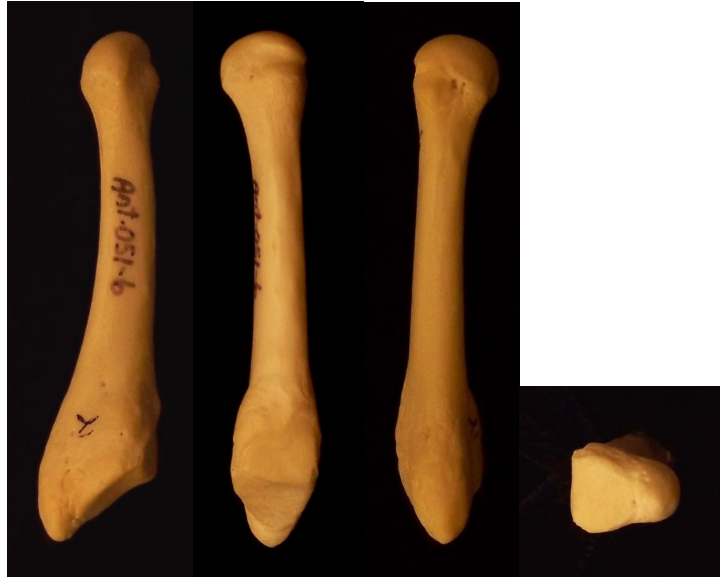Metatarsal 2. Left side. Left medial, middle left plantar, middle right lateral, right proximal base.



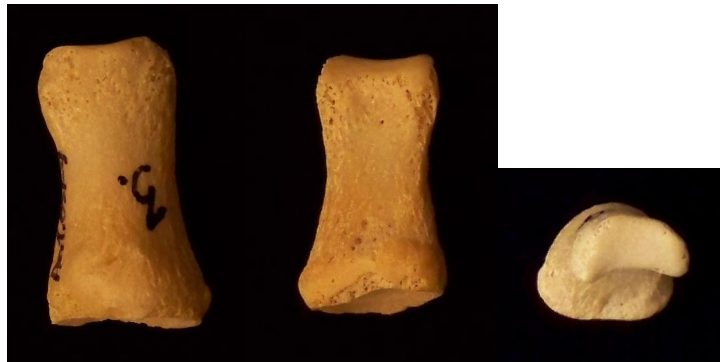
Metatarsal 3. Left side. Left medial, middle left plantar, middle right lateral, right proximal base.



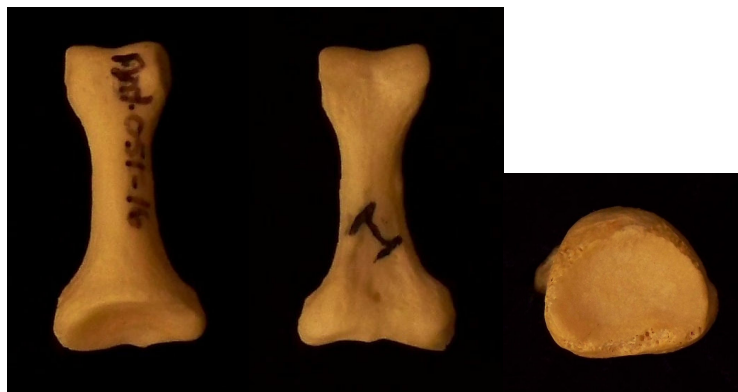
Metatarsal 4. Left side. Left medial, middle left plantar, middle right lateral, right proximal base.



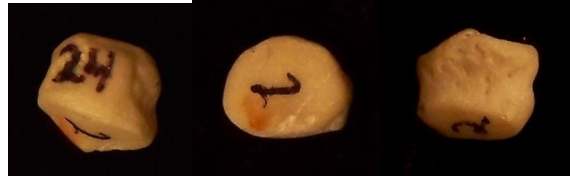Metatarsal 5. Right side. Left medial, middle left plantar, middle right lateral, right proximal base.



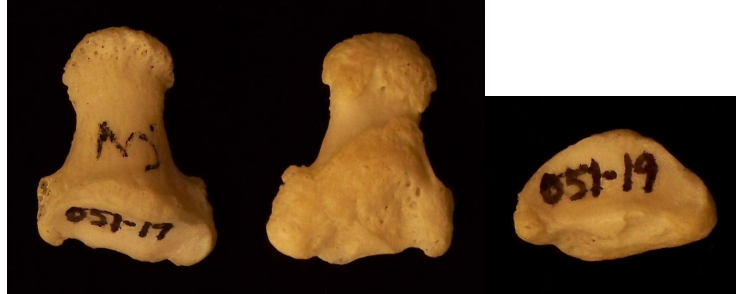Proximal Phalanges of First Toe. Left dorsal, middle plantar, right distal articulation.



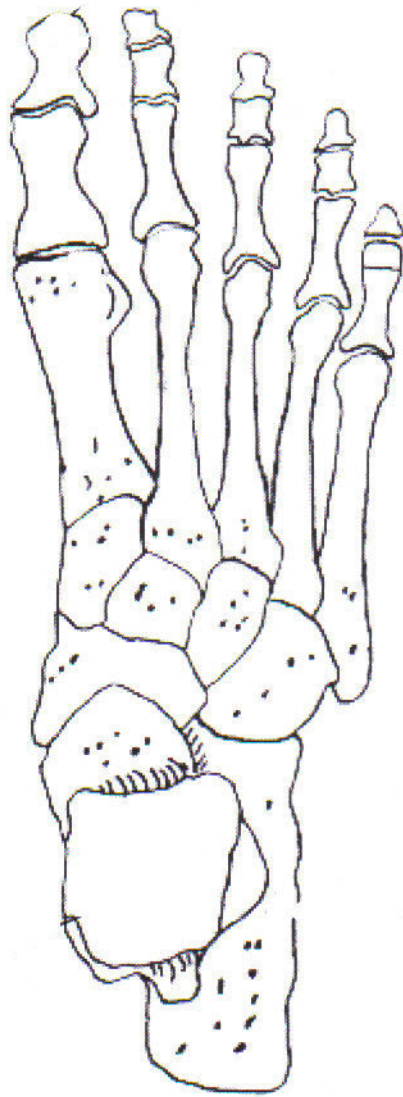
Proximal Phalanges of Non-First Toes. Left dorsal, middle plantar, right proximal base.



Medial Phalanges.



Distal Phalanges. Left dorsal, middle plantar, and right proximal base.



Foot

The Vertebral Column and Thorax

Sternum

Manubrium – bone that is trapezoidal in shape, makes up the superior aspect of the sternum.

Jugular notch – concave notches on either side of the superior aspect of the manubrium, for articulation with the clavicles.

Corpus or body – flat, rectangular bone making up the major portion of the sternum. The lateral aspects contain the notches for the true ribs, called the costal notches.

Xiphoid process – variably shaped bone found at the inferior aspect of the corpus. Process may fuse late in life to the corpus.

Clavicle

Sternal end – rounded end, articulates with manubrium.

Acromial end – flat end, articulates with scapula.

Conoid tuberosity – muscle attachment located on the inferior aspect of the shaft, pointing posteriorly.

Ribs

Head

Neck

Tubercle

Shaft

Costal groove

Scapulae

Ventral surface

Dorsal surface

Spine

Coracoid process

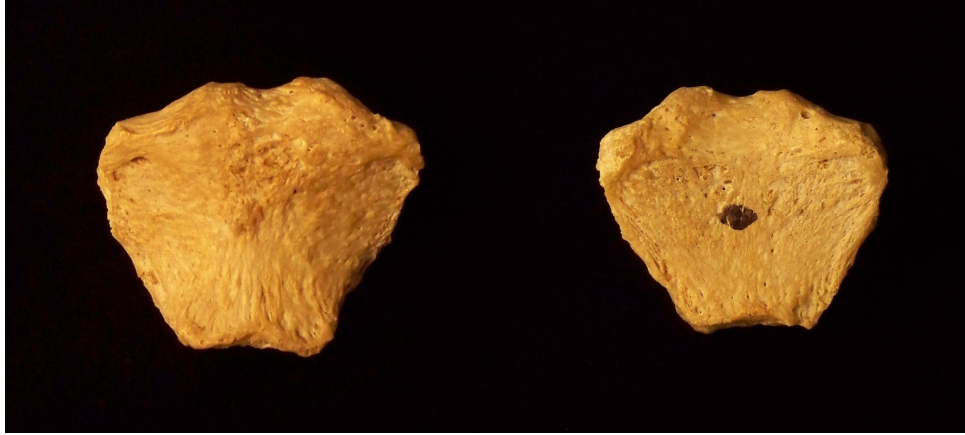
Acromion

Glenoid fossa

Axillary margin

Medial angle

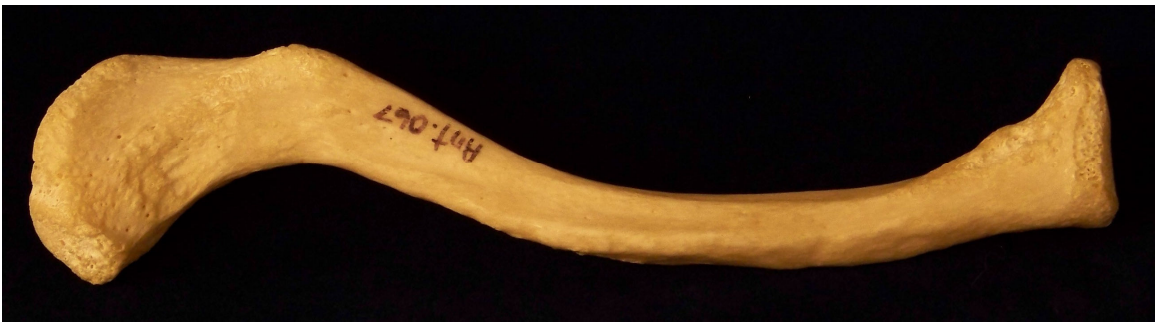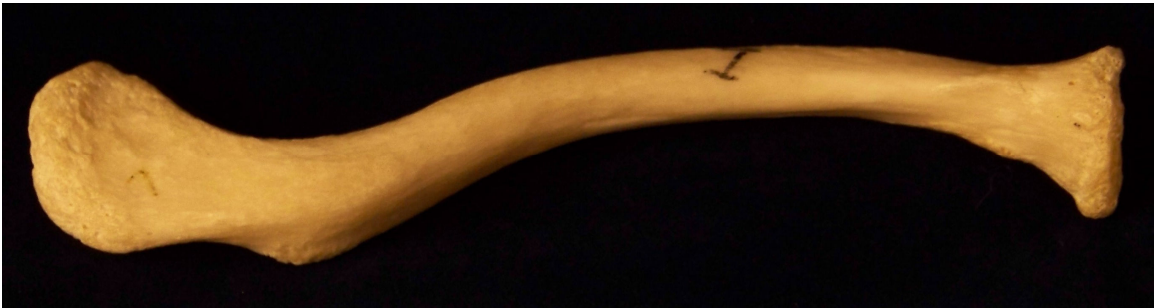Vertebral margin



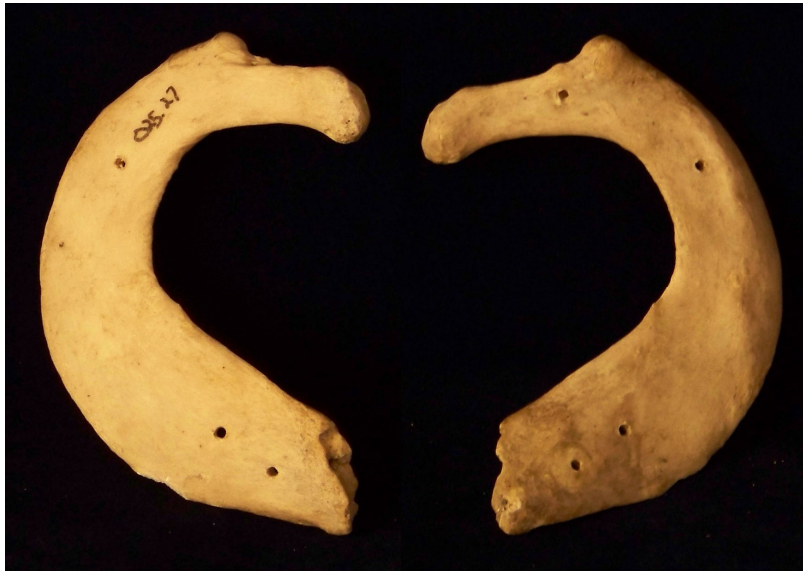Manubrium. Left anterior aspect, right posterior aspect.



Sternum and Xyphoid Process. Left anterior aspect, right posterior aspect.



Clavicle. Left side. Top superior and bottom inferior.



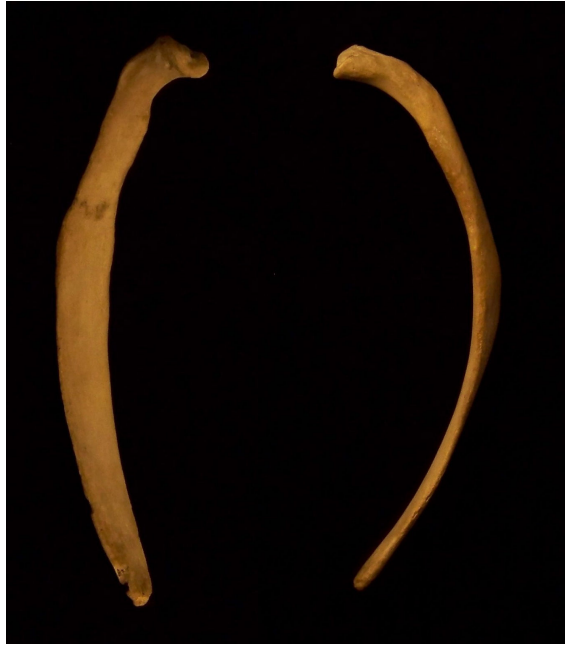First Rib. Left superior and right inferior.



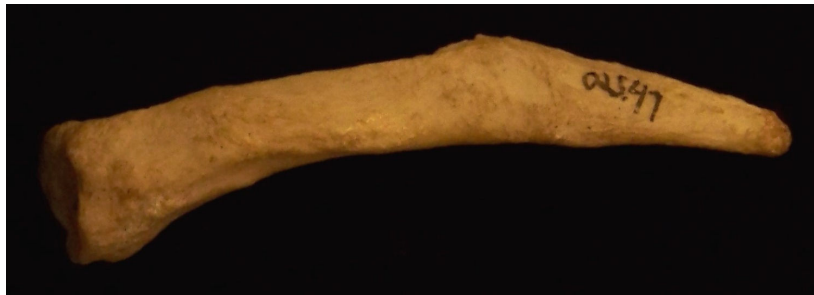Second Rib. Left inferior and right superior.



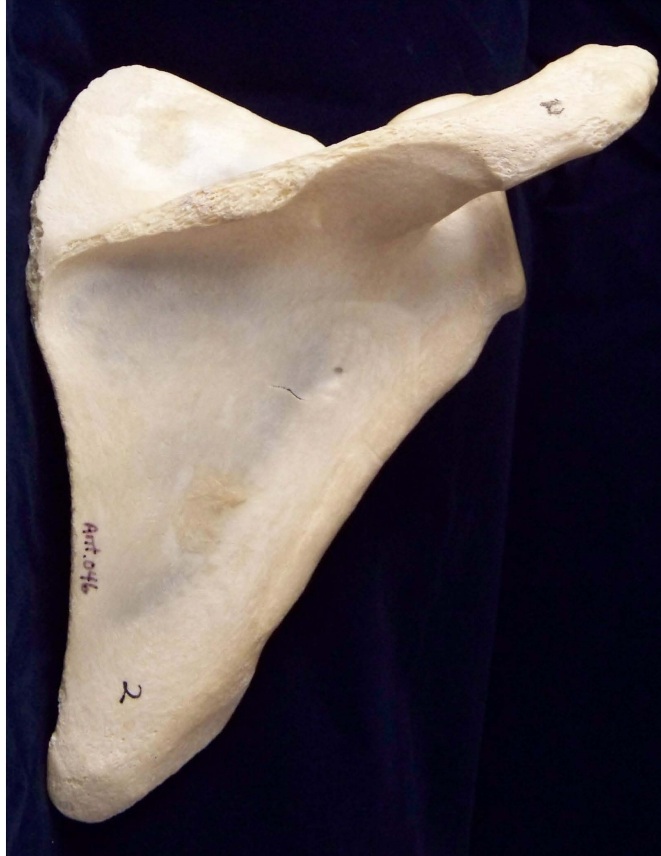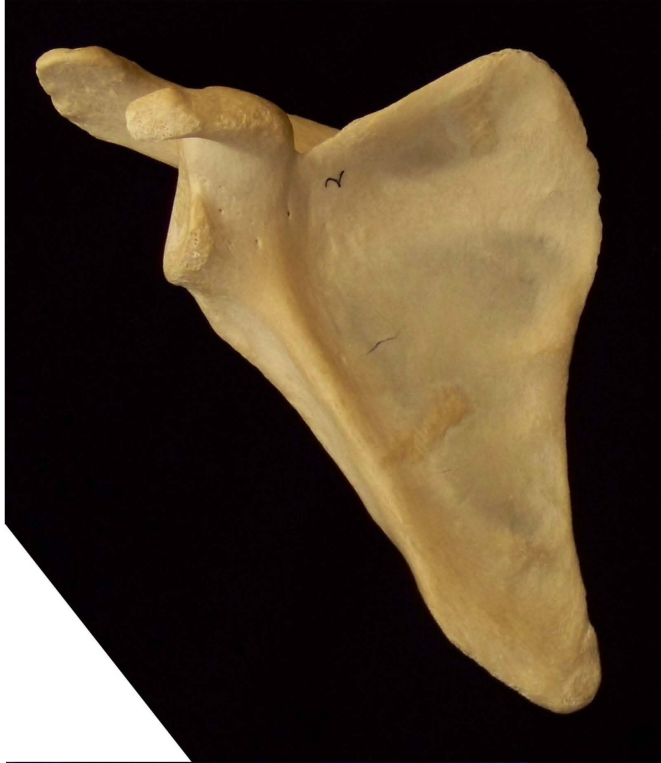Typical Rib. Left inferior and right superior.



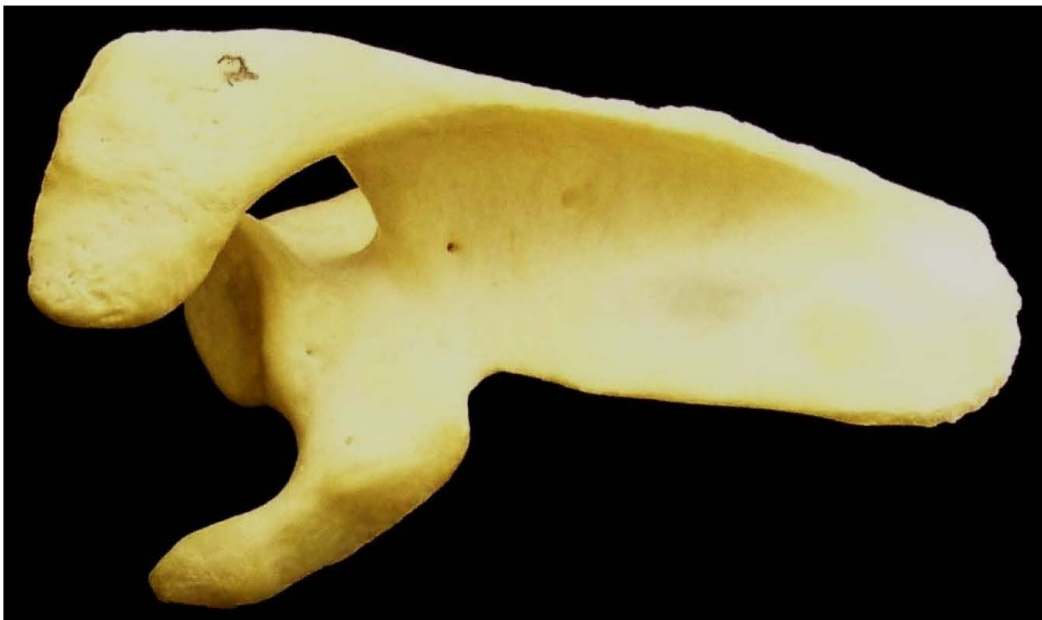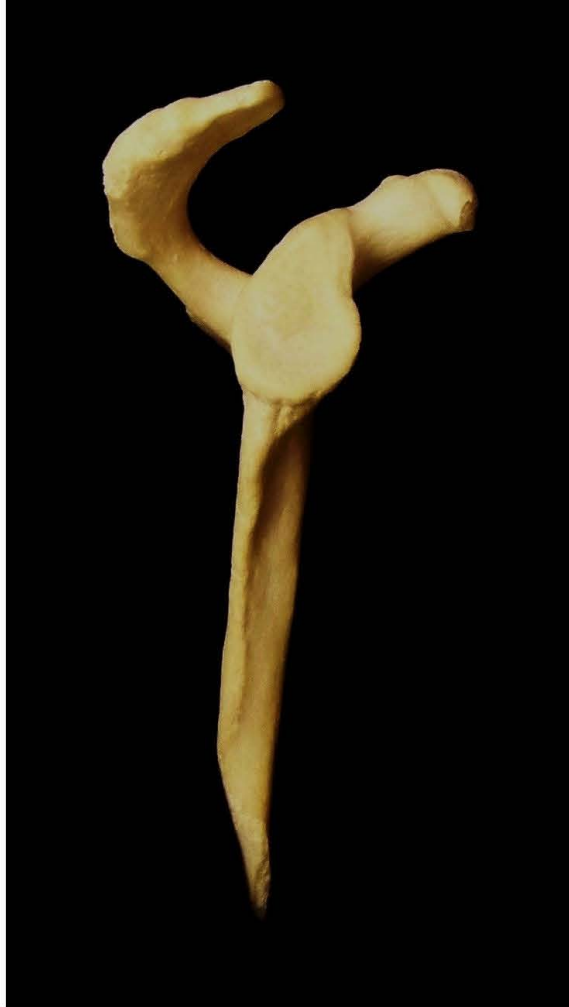Eleventh Rib. Left posterior view and left superior view.




Twelfth Rib. Top shows anterior view and bottom shows posterior view.



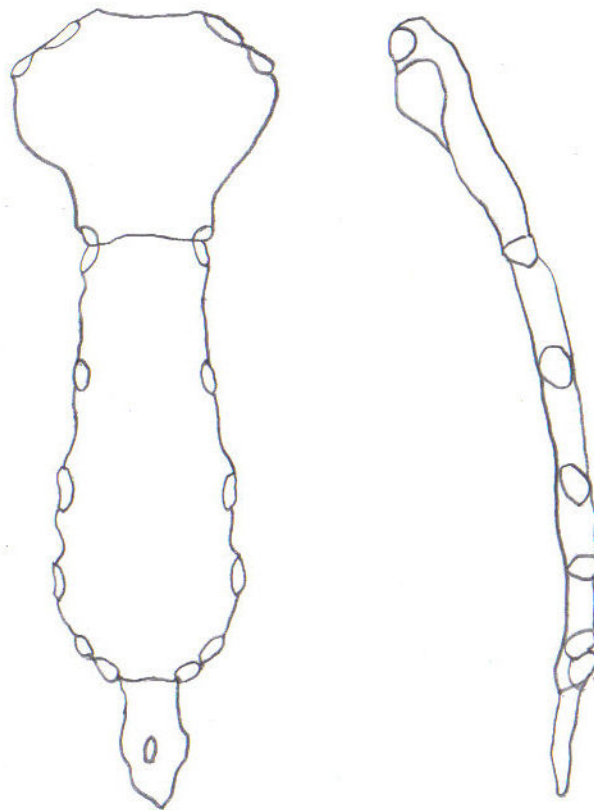
Scapula. Left side. Top anterior and bottom posterior.



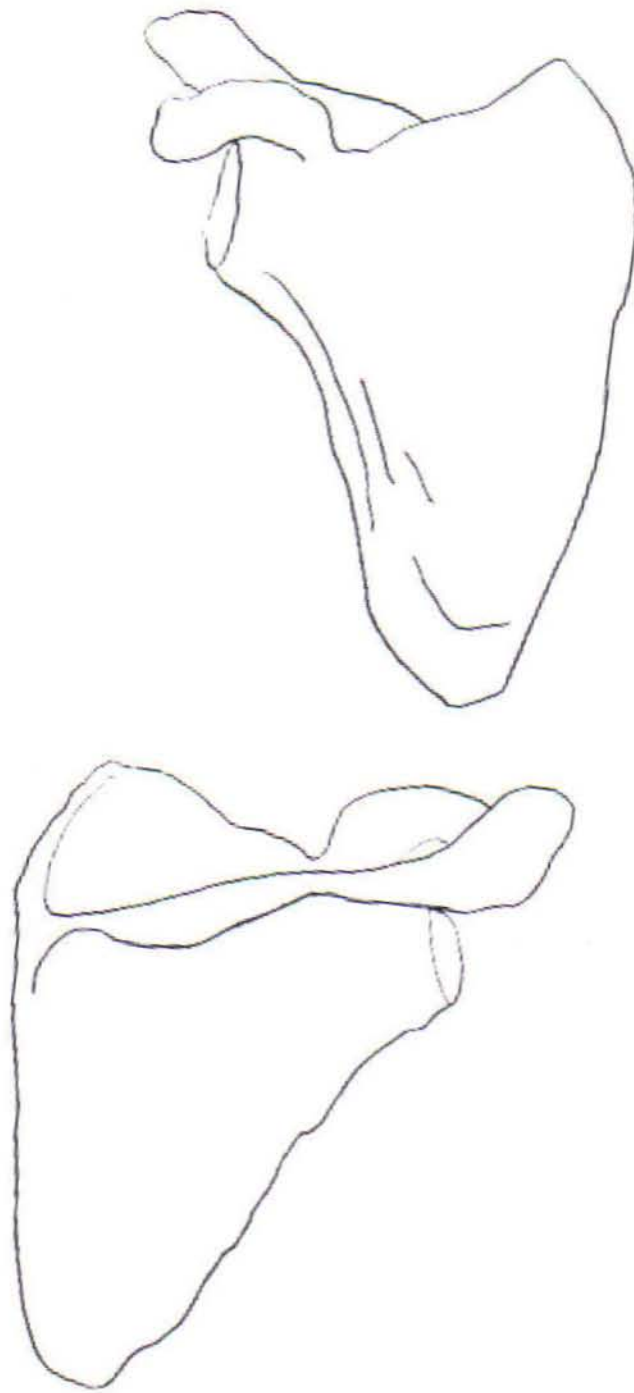
Scapula. Top lateral and bottom superior.



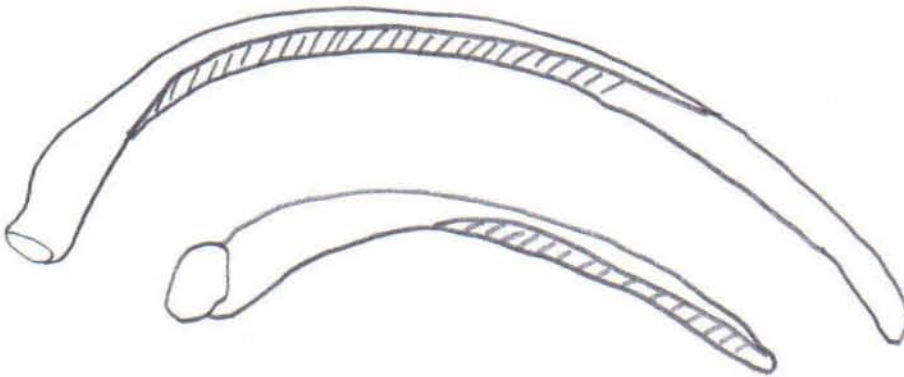
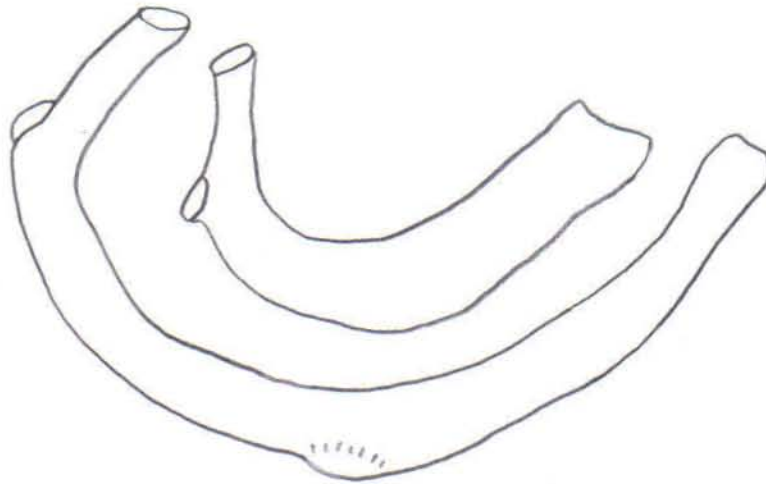

Clavicle



Sternum



Scapula



Ribs

Vertebrae

Body - Development of the vertebrae can be used in aging of individuals. In the first stage of development there are three separate portions, the two neural arches and the body. The neural arches fuse to each other first, around age 2-4 years of age. The body and neural arches later fuse at approximately 3-6 years of age. The body of a juvenile vertebra will exhibit billowing around the margins; these disappear as the end plates fuse to the body.

Foramen - Central hole through which the spinal cord passes.

Transverse foramina - Foramen on each of the transverse processes of the cervical vertebrae. Through these foramina the vertebral arteries pass.

Arches – Encloses the spinal column.

Spinous process – Posteriorly projecting aspect of the vertebra; attachment for muscles and ligaments that varies in size.

Superior articular facets & Inferior articular facets – Oval shaped facets located on the superior and inferior aspects of the posterior part of the vertebrae. As they articulate with each other, they are faced in opposite directions depending on their location in the spinal column.

Characteristics	Cervical (7)	Thoracic (12)	Lumbar (5)
Body Shape	Oval	Round	Heart
Body Size	Small	Medium	Large
Vertebral Foramen	Rounded	Round	Triangular
Transverse Process	Small	Large	Large and blunt
Transverse Foramen	Present	Absent	Absent
Spinous Process	2-6 Bifid	Long, projects inferiorly	Thick and horizontal
Articulating Facets	Superior: face posterior Inferior: face anterior	Superior: face posterior, flat Inferior: face anterior, flat	Superior: face medially, curved Inferior: face laterally, curved
Costal Facets	None	On body and transverse processes	None

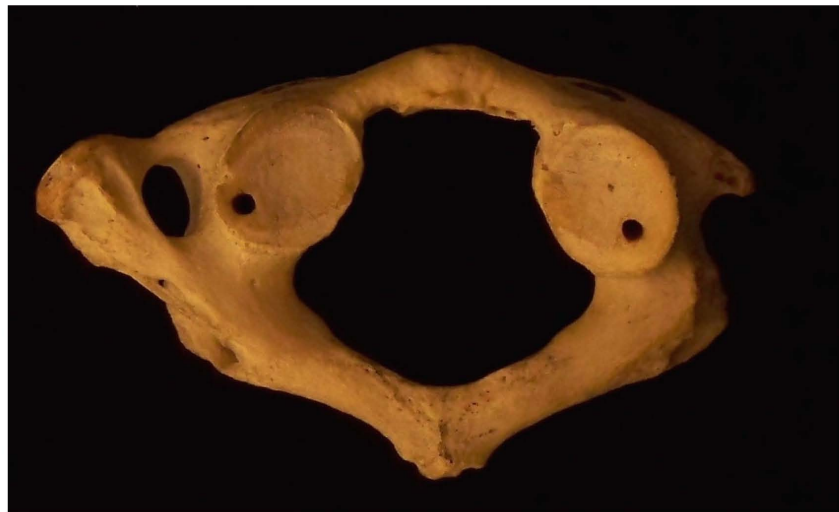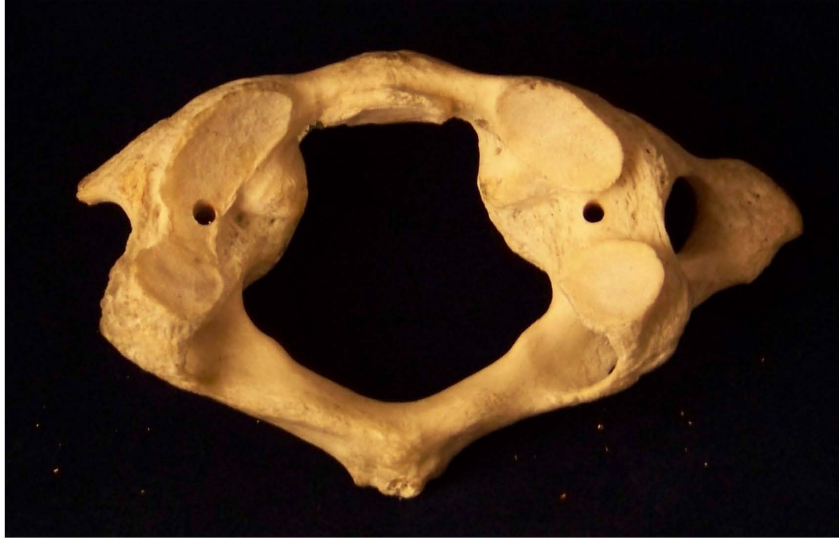Non-Metric Traits of the Vertebral Column and Thorax

Rhomboid fossa

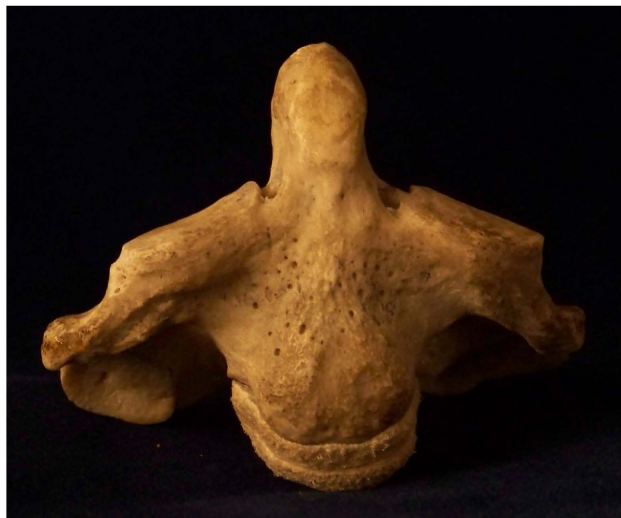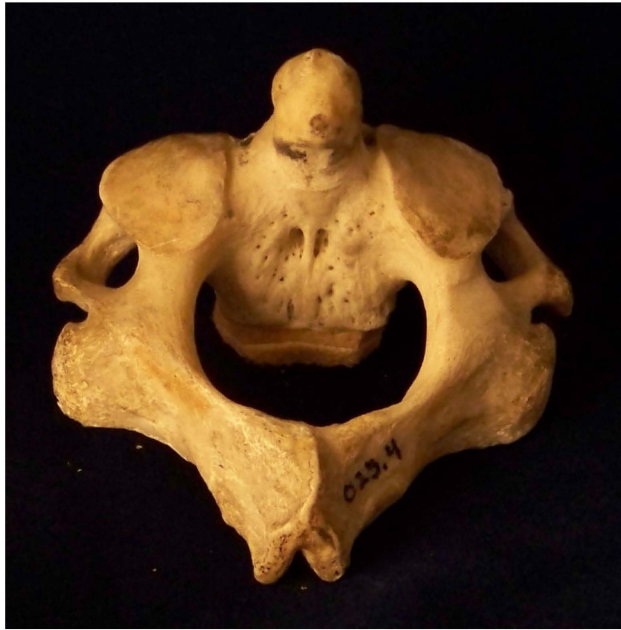In the area where the costoclavicular ligament attaches, there may be a depression, crest, or plateau.

Os acromiale

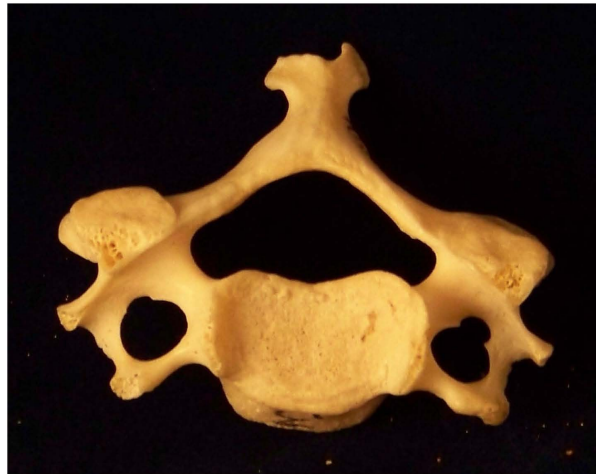
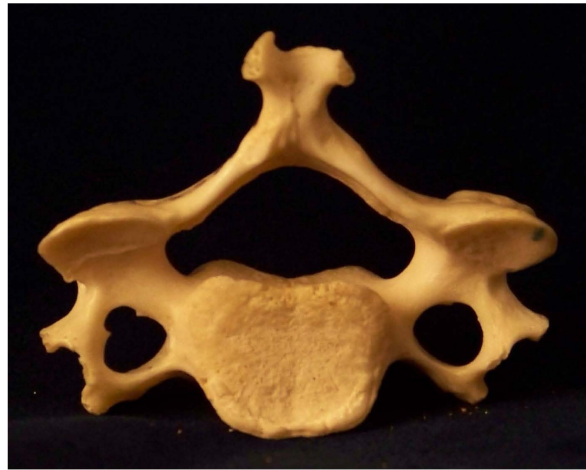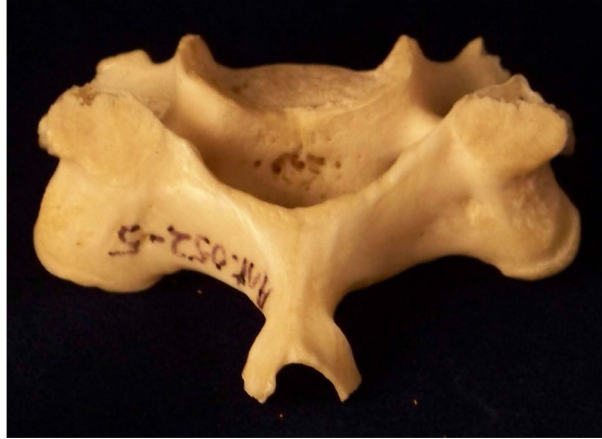
Lack of fusion of the acromial epiphysis, presents with rounded margins on the epiphysis and acromion.



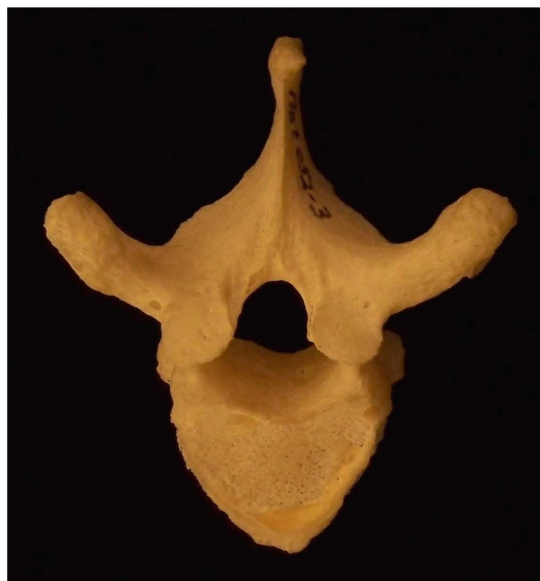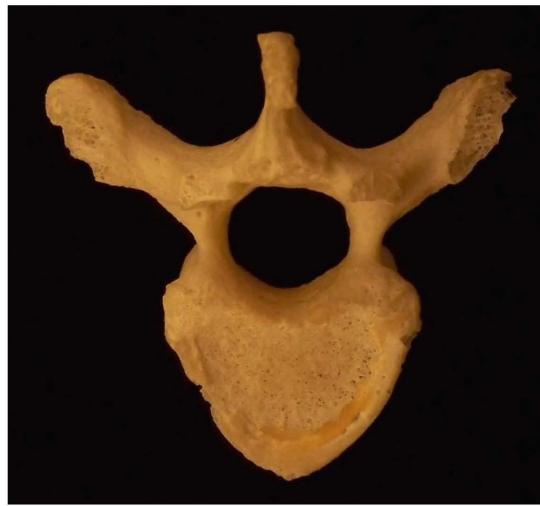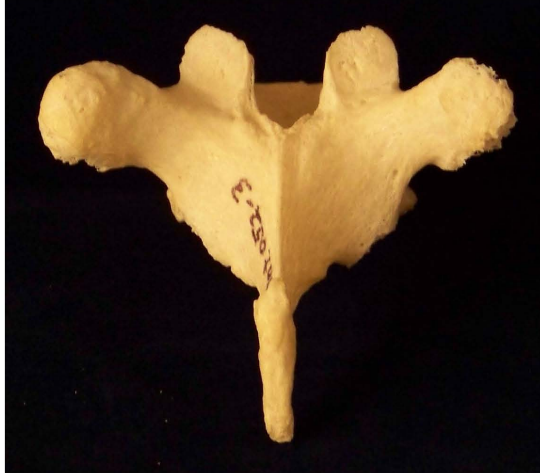Atlas. Top superior and bottom inferior.



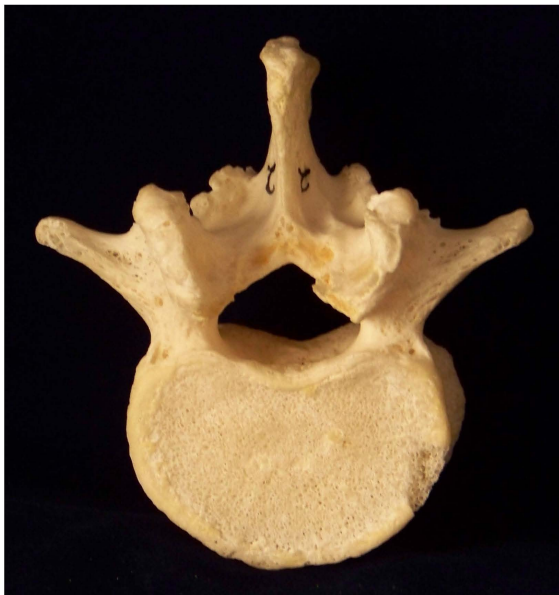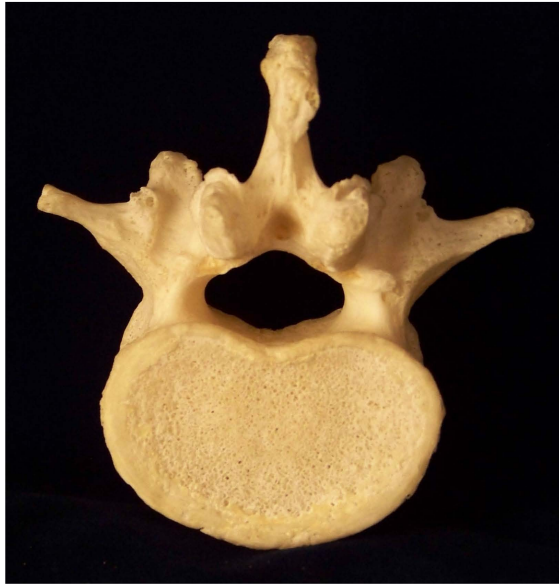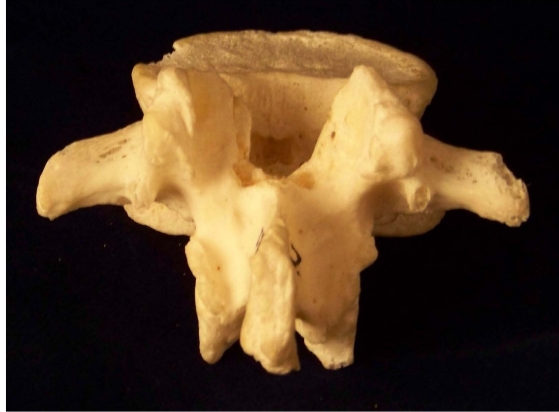Axis. Top superior and bottom anterior.



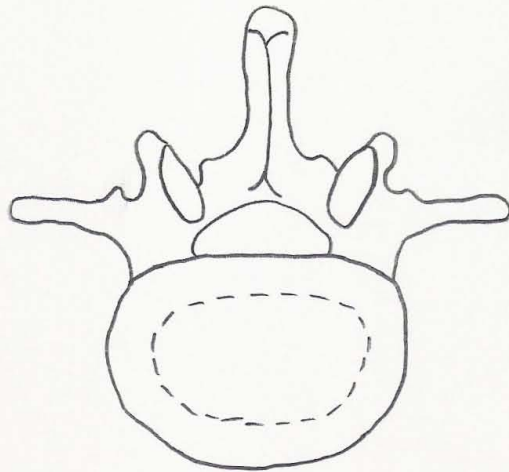
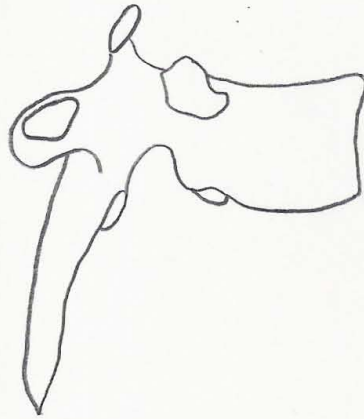
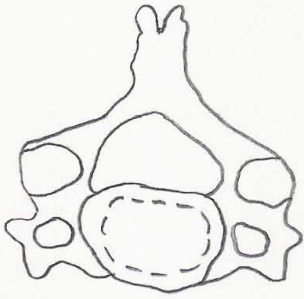
Cervical Vertebrae. Top posterior, middle inferior, bottom superior.



Thoracic Vertebrae. Top posterior, middle inferior, bottom superior.



Lumbar Vertebrae. Top posterior, middle inferior, bottom superior.



Top – Cervical. Middle – Thoracic. Bottom – Lumbar.

The Pelvic Girdle

Sacrum

A continuation of the vertebral column, the sacrum is composed of five fused vertebrae. Where the sacrum meets with the fifth lumbar vertebra it is widest, decreasing in size inferiorly. The sacrum also makes up the posterior aspect of the pelvic girdle.

Base

Apex

Promontory

Ventral surface

Transverse ridges

Anterior sacral foramina

Dorsal surface

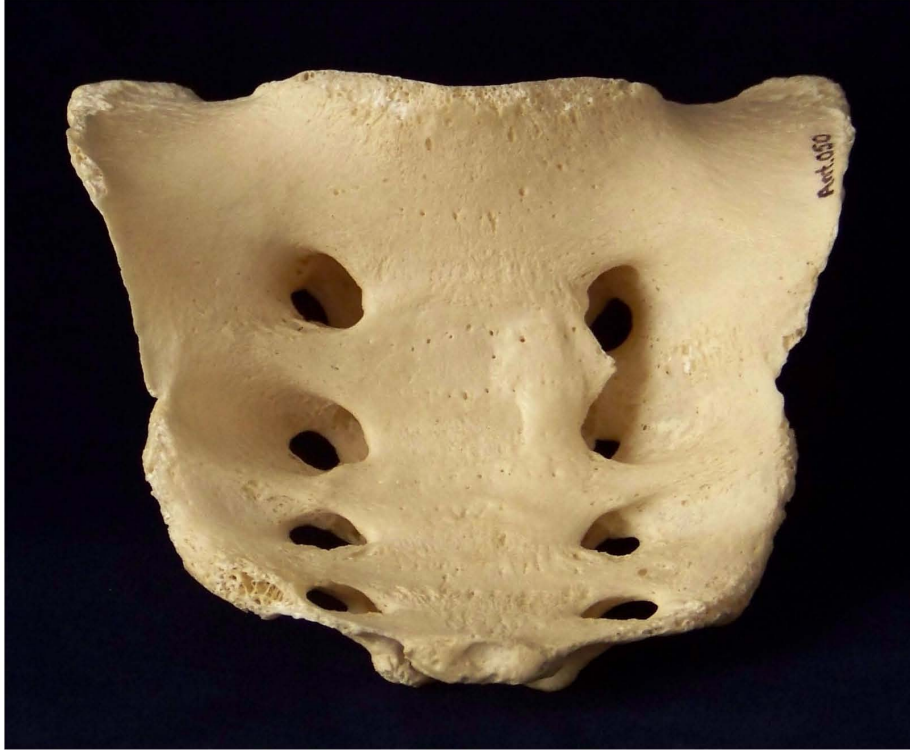Medial sacral crest

Posterior sacral foramina

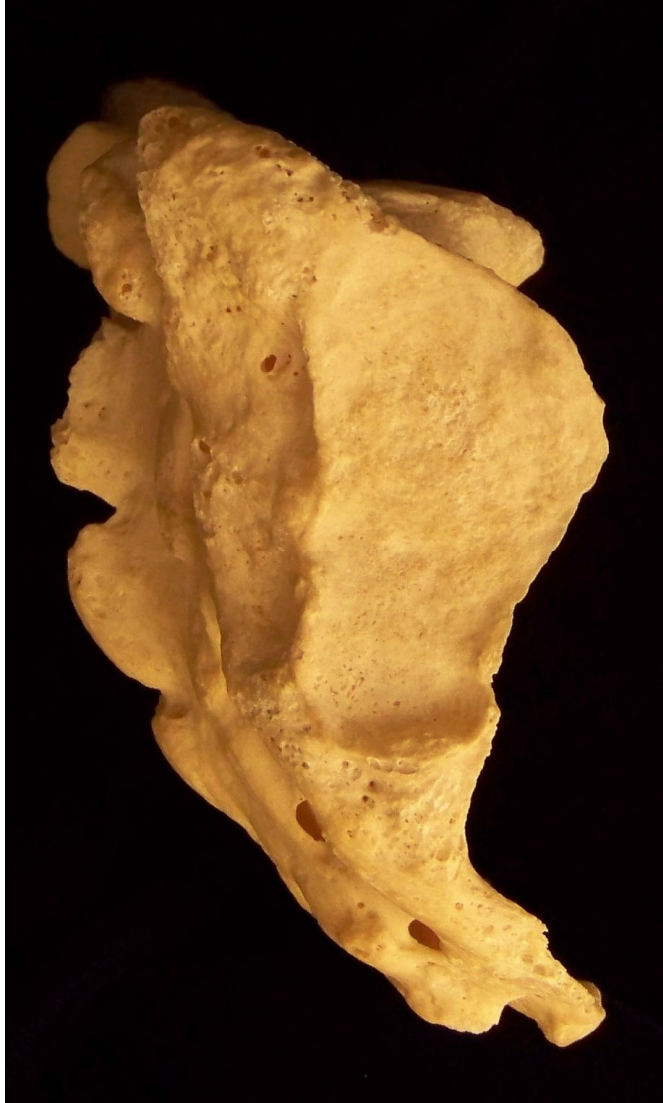Lateral surface – Wings or ala

Coccyx

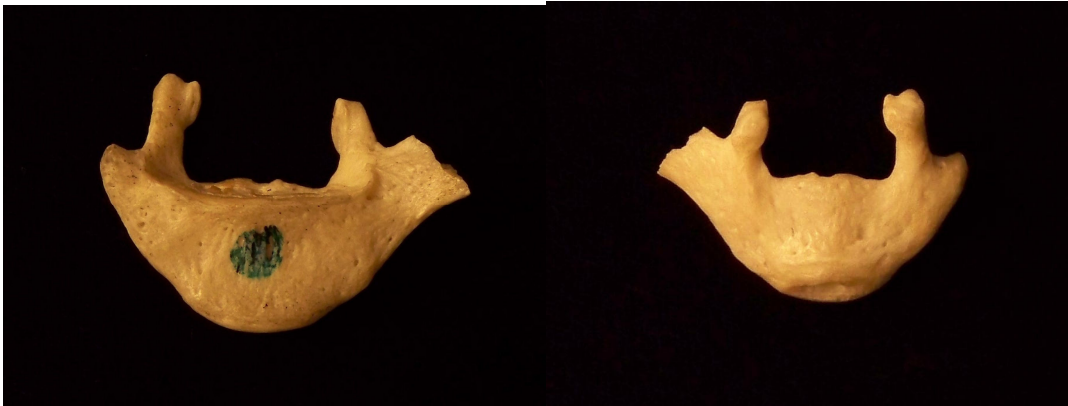
Four very small vertebrae found at the apex of the sacrum which are fused in adults, but are often absent in archaeological specimens. The corunae are the only landmarks seen on the coccyx, which are tubercles projecting superiorly from the body of the coccyx.



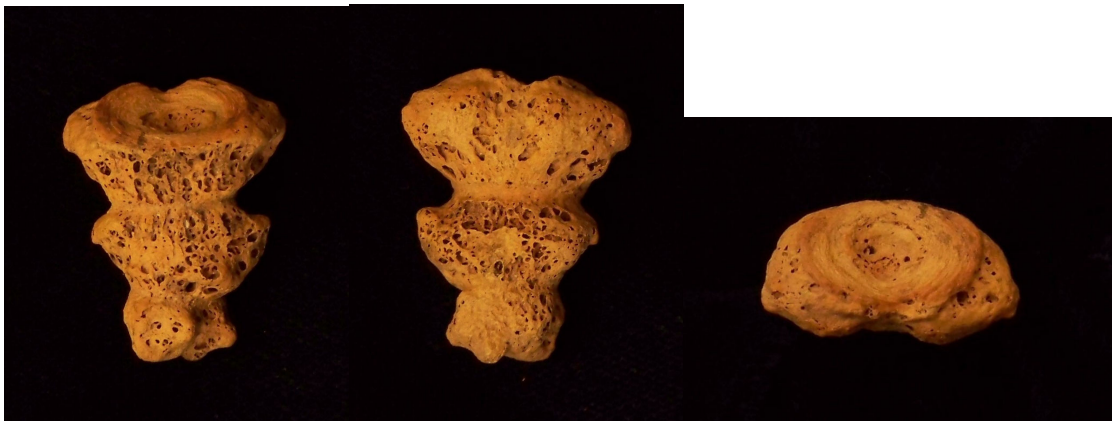Sacrum. Top anterior and bottom posterior.



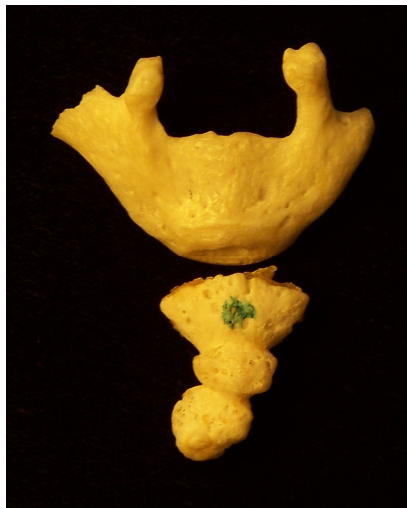Sacrum. Lateral view.



Superior coccygeal body. Left view anterior and right view posterior.



Inferior coccygeal elements. Left view anterior, middle view posterior, right view superior articulation.



Superior and inferior coccygeal elements articulated.

Innominate

The innominate is made up of three bones which fuse late during the adolescent phase, including the ilium, ischium, and pubis. The bones fuse together at the center of the acetabulum, the fossa in which the femur articulates, each making up part of the articulation.

Ilium

- Iliac crest
- Greater sciatic notch
- Lesser sciatic notch
- Iliac tuberosity
- Preauricular sulcus
- Auricular surface
- Iliac fossa
- Anterior superior and inferior spines

Ischium

- Ischial tuberosity

Pubis

- Pubic symphyses

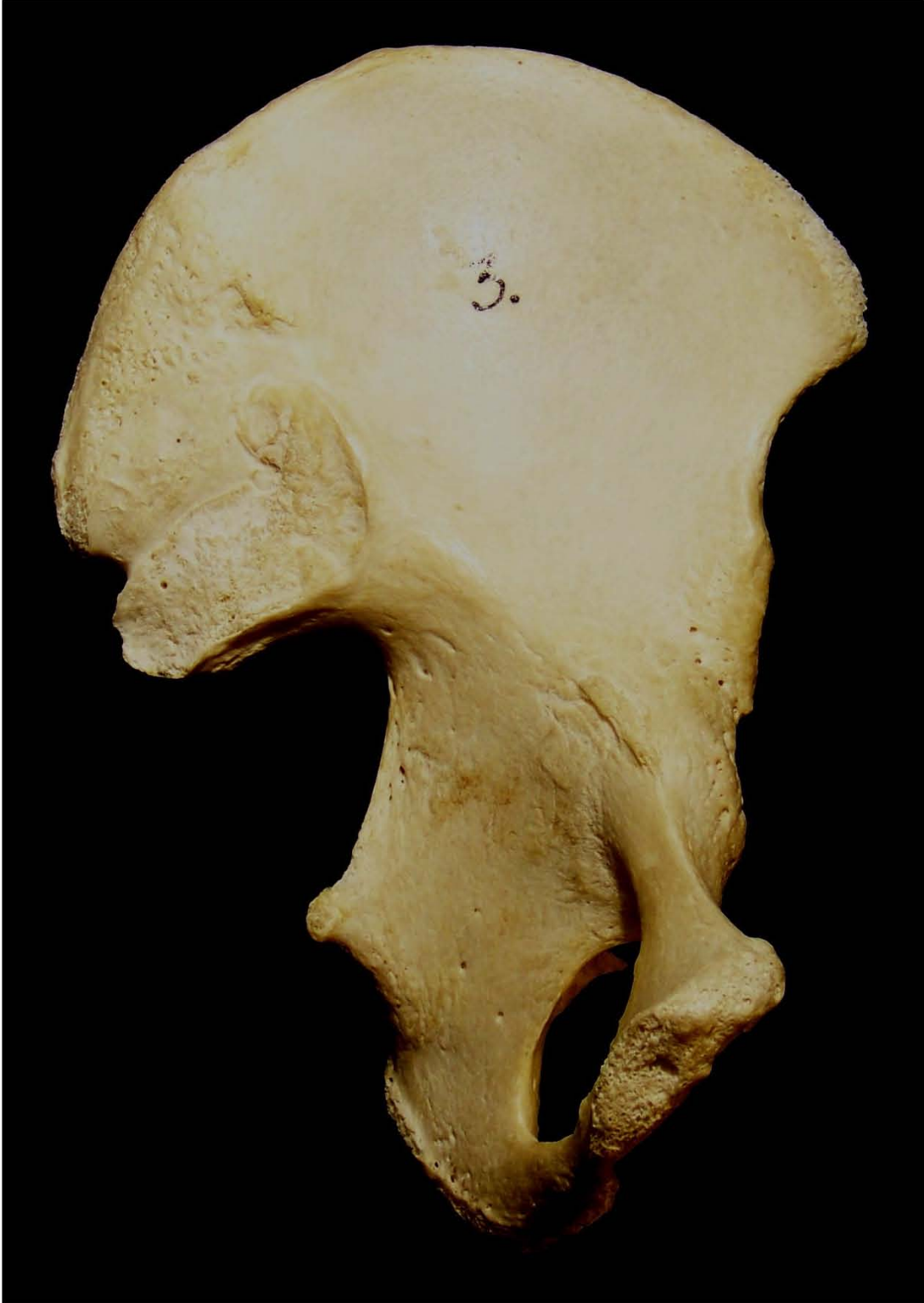Structures formed by the intersection of the three bones of the innominate:

Obturator foramen

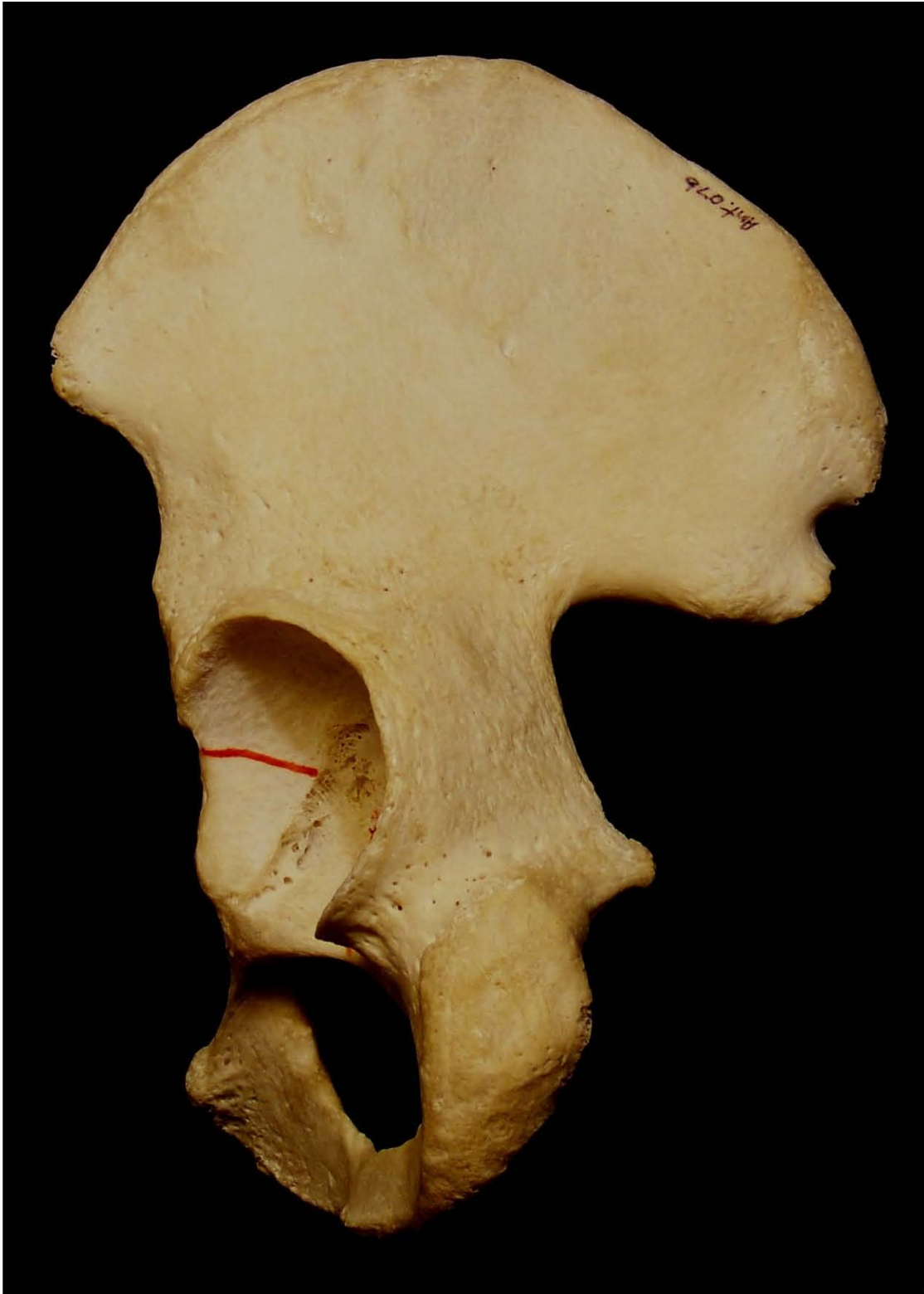Acetabulum

- Lunate face

- Fossa



Innominate. Anterior view.



Innominate. Posterior view.

Non-Metric Traits of the Pelvic Girdle

Accessory iliac facet


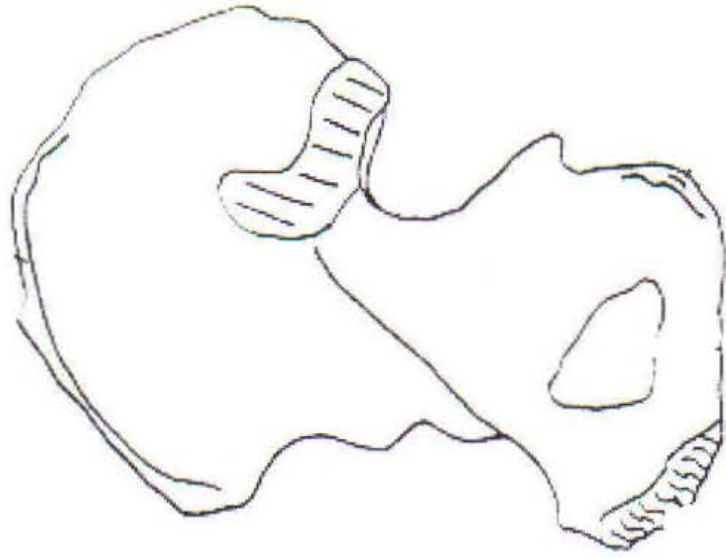
Additional facet located on the iliac tuberosity in the area that articulates with the sacrum. May be unilateral or bilateral.

Accessory sacral facet

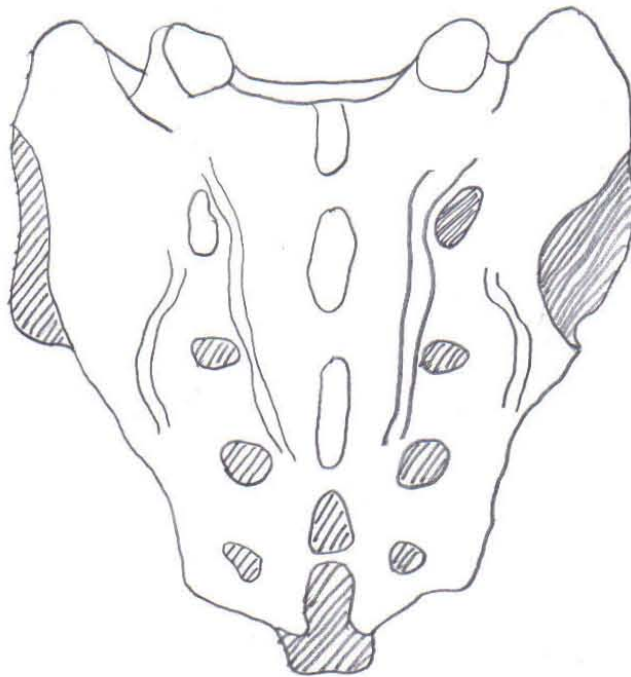
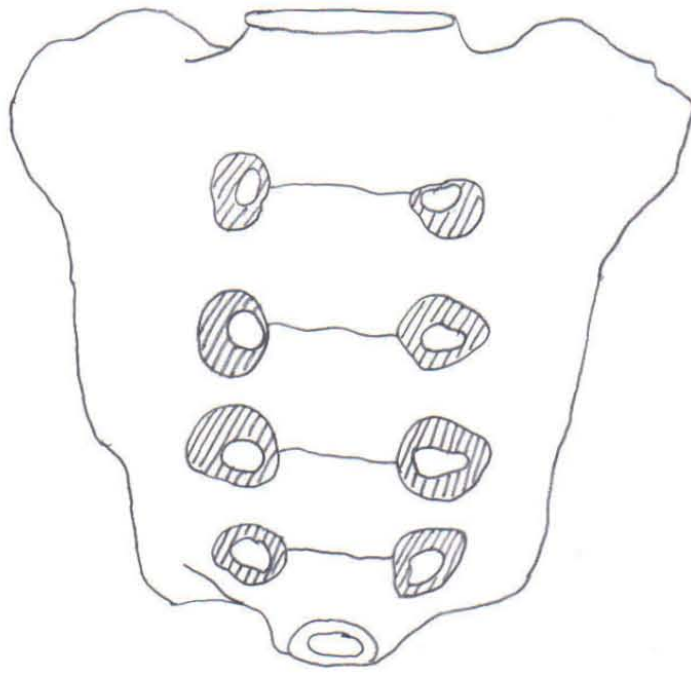
Additional facet located on the posterior aspect of the sacrum near the first sacral foramen. May be unilateral or bilateral.

Acetabular mark/notch

U-shaped depression located in the superior aspect of the acetabulum on the lunate surface. (Mann and Hunt 2005)



Innominate



Sacrum

Postcranial Measurements

For a complete list of standard postcranial measurements see Buikstra and Ubelaker (1994). Buikstra and Ubelaker (1994) have proposed a set of standard measurements and collection techniques to be employed by all practicing physical and forensic anthropologists to aid in data collection and comparison between researchers.

Aging of the Postcranium

Few options are available in aging the postcranium including epiphyseal union, bone measurements in infants, and degenerative change. Bone measurements exist for fetal material through approximately six years of age; see Johnston 1962 for further information. Degenerative change in the postcranium is similar to that seen in the articulation sites in the skull, with osteophytosis and erosion. Epiphyseal union can be extremely helpful in aging if no dentition is present or if you are working with a commingled burial. Presence, absence, and fusion of the epiphyses to the shaft of the bone is a relatively easy observation; see below for further information on aging using fusion of the epiphyses.

Epiphyseal Union

As a child an individual may have up to 600 separate bones, but by adulthood only 206 are present. This is due to the fact that there are both primary and secondary centers of ossification; as an individual ages the secondary centers will fuse to the primary centers. Below are some age estimates for when epiphyseal union occurs:

Clavicle	Sternal epiphysis fused by 25 years of age (Bass 1995)
Femur	Head and greater trochanter fused between 14-19 years of age (Bass 1995)
Fibula	Proximal epiphysis fused by 14-22 years of age Distal epiphysis fused by 11-20 years of age (Bass 1995)

Humerus	Head fused by age 24 years of age Medial epicondyle fused by age 19 years of age Distal epiphysis fused between 17-18 years of age (McKern and Stewart 1957)
Iliac Crest	Fused by age 23 (McKern and Stewart 1957)
Innominate	Pubis to ischium fused between 7-8 years of age Fusion of the pubis/ischium/ilium at the acetabulum by at least 17 years of age (Bass 1995)
Ischial Tuberosity	Fused by age 24 (McKern and Stewart 1957)
Radius	Proximal epiphysis fused between 16-18 years of age Distal epiphysis fused between 16-18 years of age (Bass 1995)
Ribs	Head and articular end fused between 18-24 years of age (Bass 1995)
Sacrum	Fuses from inferior to superior between the ages of 18-25 (Bass 1995)
Tibia	Proximal epiphysis fused between 14-23 years of age Distal epiphysis fused between 13-20 years of age (Bass 1995)
Ulna	Proximal epiphysis fused by 19 years of age Distal epiphysis fused between 17-20 years of age (Bass 1995)

Sex Estimation of the Pelvis

The pelvis is an ideal anatomical structure to use in sex estimations of adult specimens, because of the obvious functional relationship between pelvic shape and reproduction in the female. Many studies have been done to determine pelvic characteristics useful in sex estimations. The most easily identified indicators will be mentioned in this text. The first two are generally the most useful, especially for the budding osteologist. Clearly, the more experience an osteologist has in making sex estimations and the greater number and range of pelvises examined, the better the estimations will be.

1. Sub-pubic angle. The inferior angle that the right and left pubic bones make when in articulation tend to be wider in females than in males; a wider angle produces a larger pelvic outlet. Angles closer to 90 degrees suggest male sex, while those 120 degrees and over would suggest a female. The female pelvis is shorter and broad to aid in the birthing process, since the male pelvis lacks this necessity it is slightly taller and more narrow.
2. Sciatic notch. A narrow sciatic notch is associated with a restricted pelvic outlet and is more commonly found in males; the sciatic notch of females tends to be wider.
3. Acetabulum. The acetabulum is larger in males, due to the larger size of the femoral head in males. As males are generally larger, the femur is larger to transmit the weight of the body.
4. Obturator foramen. The obturator foramen tends to be larger in males and rather oval in outline, whereas in females it is smaller and more triangular.
5. Pre-auricular groove. The pre-auricular groove is found in some individuals of both sexes but it tends to be irregularly pitted in females if the pelvic joint ligaments that attach there are stressed in childbirth, thus a pitted pre-auricular groove indicates an estimation of female sex. However, an absence of the groove or a non-pitted form does not indicate male sex.
6. Sacrum. The sacrum of the male tends to be relatively longer, narrow, and curved. On the other hand, the female sacrum is broader, short, and straight.
7. Pelvic inlet. The pelvic inlet of the male pelvis, when viewed from above with the ventral aspect facing you, will be heart shaped in appearance. The female pelvic inlet, when held in the same aspect, is described as elliptical in appearance.
8. Dorsal pitting. Pits or depressions located on the dorsal aspect of the pubis, near the pubic symphysis. One or more may be present. The pits have been associated with pregnancy; number of pits does not necessarily represent number of births but the process of stretching during the birthing process.

Sex Estimation of the Non-Pelvic Postcranial Bones

Sex estimation of the non-pelvic postcranial bones can be very difficult, based on research with accuracy well below 90%. Keep this in mind when employing sex estimation on these bones. However, if observing several of the bones of a single individual you will greatly increase your sex estimation accuracy. Those listed below offer the highest levels of accuracy.

Humerus – A vertical (superior/inferior) measurement of the head, and a transverse (anterior/posterior) measurement of the head can be used in sexing.

	Vertical	Transverse
Female	42.67	36.98
Male	48.76	44.66

Femur – A measurement of the greatest diameter of the femoral head may be useful in determining sex. Keep in mind there may be populational differences.

	Female	Probable Female
White Female ^a	<42.5	42.5-43.5
Black Female*	41.52	
	Male	Probable Male
White Male ^a	>47.5	46.5-47.5
Black Male*	47.17	

^a Stewart 1979:120

*Thieme 1957: Table 1

Stature Estimation

Stature or height can be measured using any of the long bones, although the femora are considered the best option for obtaining the highest accuracy rate. A number of factors appear to influence height including sex, nutrition, geographic location, and genetics. It is suggested that stature formulae specific to sex and a particular geographic location or ethnic group be used to ensure accuracy. Below several formulae are shown after Bass (1995):

Male

Femur	White	$2.32(\text{femur in cm}) + 65.53 \pm 3.94$
	Black	$2.10(\text{femur in cm}) + 72.22 \pm 3.91$
	Mongoloid	$2.15(\text{femur in cm}) + 72.57 \pm 3.80$
	Mexican	$2.44(\text{femur in cm}) + 58.67 \pm 2.99$
Tibia	White	$2.42(\text{tibia in cm}) + 81.93 \pm 4.00$
	Black	$2.19(\text{tibia in cm}) + 85.36 \pm 3.96$
	Mongoloid	$2.39(\text{tibia in cm}) + 81.45 \pm 3.27$
	Mexican	$2.36(\text{tibia in cm}) + 80.82 \pm 3.73$
Fibula	White	$2.60(\text{fibula in cm}) + 75.50 \pm 3.86$
	Black	$2.34(\text{fibula in cm}) + 80.07 \pm 4.02$
	Mongoloid	$2.40(\text{fibula in cm}) + 80.56 \pm 3.42$
	Mexican	$2.50(\text{fibula in cm}) + 75.44 \pm 3.52$
Humerus	White	$2.89(\text{humerus in cm}) + 78.10 \pm 4.57$
	Black	$2.88(\text{humerus in cm}) + 75.48 \pm 4.23$
	Mongoloid	$2.68(\text{humerus in cm}) + 83.19 \pm 4.16$
	Mexican	$2.92(\text{humerus in cm}) + 73.94 \pm 4.24$
Radius	White	$3.79(\text{radius in cm}) + 79.42 \pm 4.66$
	Black	$3.32(\text{radius in cm}) + 85.43 \pm 4.57$
	Mongoloid	$3.54(\text{radius in cm}) + 82.00 \pm 4.60$
	Mexican	$3.55(\text{radius in cm}) + 80.71 \pm 4.04$

Ulna

White	$3.76(\text{ulna in cm}) + 75.55 \pm 4.72$
Black	$3.20(\text{ulna in cm}) + 82.77 \pm 4.74$
Mongoloid	$3.48(\text{ulna in cm}) + 77.45 \pm 4.66$
Mexican	$3.56(\text{ulna in cm}) + 74.56 \pm 4.05$

Female

Femur*	White	$2.47(\text{femur in cm}) + 54.10 \pm 3.72$
	Black	$2.28(\text{femur in cm}) + 59.76 \pm 3.41$
Tibia*	White	$2.90(\text{tibia in cm}) + 61.53 \pm 3.66$
	Black	$2.45(\text{tibia in cm}) + 72.65 \pm 3.70$
Fibula*	White	$2.93(\text{fibula in cm}) + 59.61 \pm 3.57$
	Black	$2.49(\text{fibula in cm}) + 70.90 \pm 3.80$
Humerus*	White	$3.36(\text{humerus in cm}) + 57.97 \pm 4.45$
	Black	$3.08(\text{humerus in cm}) + 64.67 \pm 4.25$
Radius*	White	$4.74(\text{radius in cm}) + 54.93 \pm 4.45$
	Black	$3.67(\text{radius in cm}) + 71.79 \pm 4.59$
Ulna*	White	$4.27(\text{ulna in cm}) + 57.76 \pm 4.30$
	Black	$3.31(\text{ulna in cm}) + 75.38 \pm 4.83$

*After Trotter and Gleser (1952:495, 1977:355)

Post-Cranial Pathology and Trauma

Arthritis/Degenerative Joint Disease - Arthritis can be caused by a number of different factors both genetic and behavioral. Age of the individual should be noted to make the best possible diagnosis of type of arthritis observed. Osteophytes or small spicules of bone may be present at the margins of the joint or within the joint itself. A ridge of osteophytic change may also be present around the margin of the joint. Erosion is frequently seen along with osteophytosis; which may be seen as increased porosity or pitting.

Eburnation – Extreme erosion may occur when the soft tissue within a joint when cartilage is no longer present. The result is bone on bone contact that creates grooving on the surface of the joint, overall making a smooth shiny surface. (Aufderheide and Rodriguez-Martin 1998)

Enthesopathy – Calcified muscular or ligamentous attachments. Most often seen at the site of the Achilles tendon attachment site, ischial tuberosities, and ilial crests. (Aufderheide and Rodriguez-Martin 1998)

Fractures – Several types of fractures occur in the postcranial bones including, greenstick, impacted, simple, compound, comminuted, compressed, spiral, Colles's, and parry.

Schmorl's Nodes - Depression or cavity caused by herniation of the vertebral disc. Located on either the superior or inferior aspect of the body of a vertebra. The depressions are oval or linear in shape, with relatively smooth margins. Generally seen as a sign of advanced age. (Mann and Hunt 2005)

Spina Bifida - Incomplete closure of the neural arches of the sacral vertebrae. Note that the sacral vertebrae four and five may be open naturally. This condition is both genetic and environmentally controlled. (Mann and Hunt 2005)

Dentition

Two parts make up the structure of teeth: a portion within the mouth called the crown, and a portion within the jaw called the root. The outer surface of the crown seen in the mouth is a hard white substance called enamel. Directly beneath the enamel is a softer material called dentine. The central portion of the root contains the pulp or nerve bundle feeding the tooth, called the pulp chamber. The root itself is made of dentine and is covered on the outside with a protective substance called dentine.

Observe the crowns of the teeth as seen while in the jaw. Note that the number of teeth is the same in both the upper and lower jaw. There are four types of teeth present in the upper and lower jaw: 4 incisors, 2 canines, 4 premolars, and 6 molars for a total of 32 teeth. For comparative purposes in the study of evolutionary change, it is customary to represent the dentition by the number of teeth in each quadrant of the mouth, as 2.1.2.3.

The incisors are generally chisel-shaped, though some persons including most American Indians many have lateral ridges making them shovel-shaped (particularly the upper incisors). The upper incisors are generally wider than the lowers. The canines are more massive than incisors and when unworn are slightly projecting and pointed. Due to the narrowness of the lower incisors the lower canine usually occludes slightly forward of the upper one. The premolar or bicuspid teeth are distinguished by 2 cusps, one lingual (on the tongue side) and one buccal (on the cheek side). In the molar teeth a distinction may be made between uppers and lowers. The lower molars are square or rectangular in shape, with 4-5 cusps. The more anterior of these are generally larger decreasing posteriorly and have a more complicated cusp pattern. The upper molars are in general smaller than the lowers, and also decrease in size posteriorly. Three to four cusps are generally seen in the upper molars; if three are present, two will be on the buccal side and one on the lingual. In addition, the outline of the upper molar tends to be slightly oblique rather than rectilinear as in the lowers.

Roots of the teeth are also helpful in determining if they are uppers/lowers and siding. The roots of the incisors and canines are single, rounded, and tapering, often curved at the ends. That of the canine is considerably longer and stouter than those of the

incisors. The roots of the premolars are wider and tend to be grooved in a fashion which indicates an incipient tendency to be divided into a lingual and buccal root. The roots of the molar teeth are quite distinct as between the upper and lower. The roots of the lower molars are double, having an anterior and posterior component, each generally grooved like the root of a premolar. The third lower molar generally has all parts of the root fused and somewhat curved. The typical root pattern of the upper molar is two distinct roots on the buccal side and one on the lingual side. In the second upper molar the three roots are often less widely spread than in the first, and in the third a single massive fused root is found. Individual variations make it difficult to identify loose molars exactly.

Many types of variation, often involving accessory cusps are found. Occasionally deciduous teeth will be encountered. In addition to having smaller crowns, deciduous teeth are recognized by the thinness and wide divergence of the molar roots.

Teeth of non-industrial peoples are often deeply worn, as more processing of food occurs within the mouth. The type of wear seen in the dentition and the kind of pathology present give an indication of the diet and the cultural habits of the individual. Microscopic study of sections taken through the teeth can provide additional information about the individual's health and nutritional status.

Terms

Buccal – The surfaces of the premolars and molars facing toward the cheek.

Cusp – A protuberance on the grinding surface of the canine, pre-molar, or molar.

Distal – The tooth surface farthest from the median line of the dental arch (posterior aspect).

Incisal edge – The cutting edge of an incisor.


Labial – The surfaces of the incisors and canines facing toward the lips.

Lingual – The tooth surfaces facing toward the tongue.

Mesial – The tooth surface closest to the median line of the dental arch (anterior aspect).

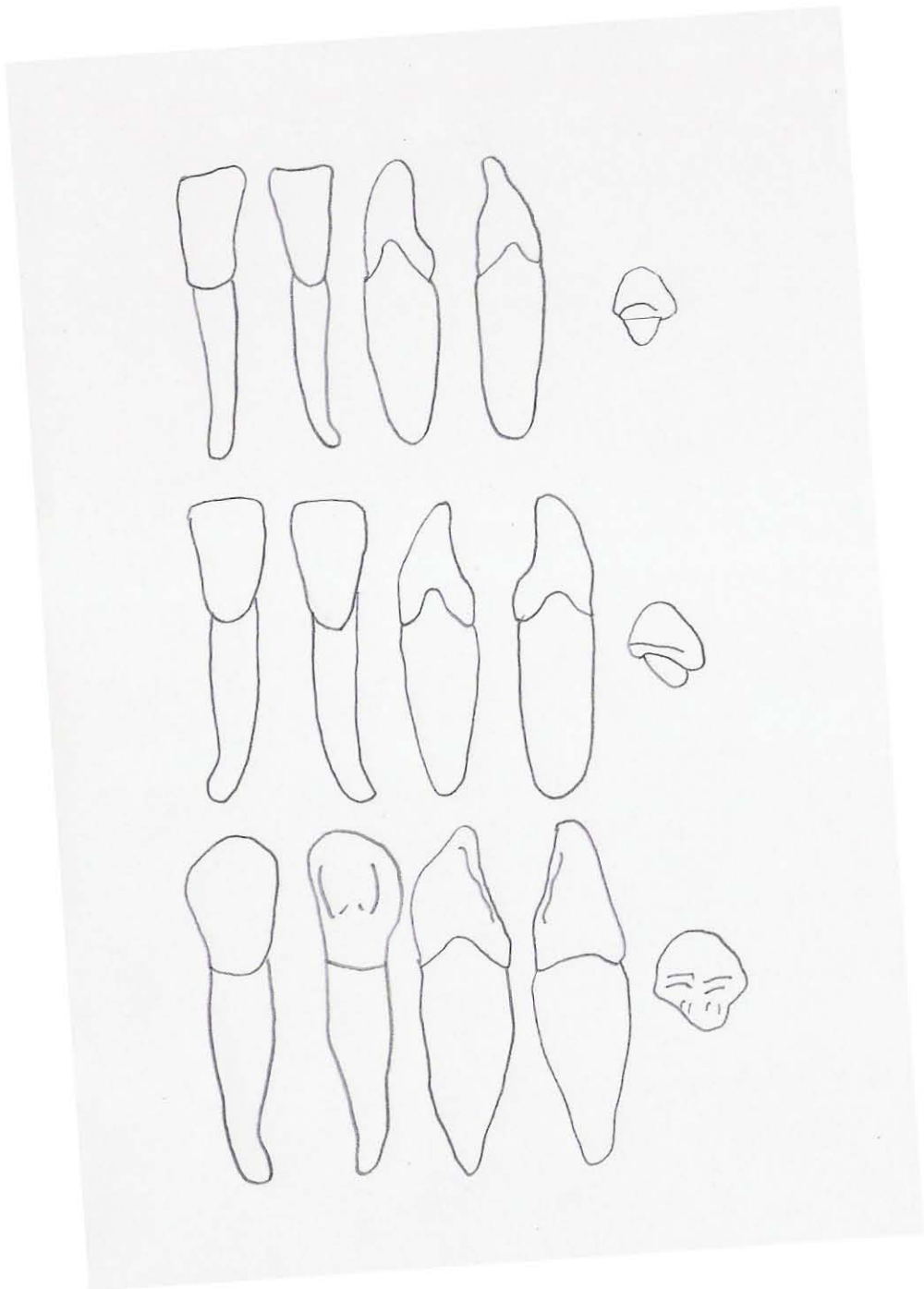
Occlusal surface – The biting or grinding surface of a tooth.

Ridge – A linear elevation on a tooth surface.



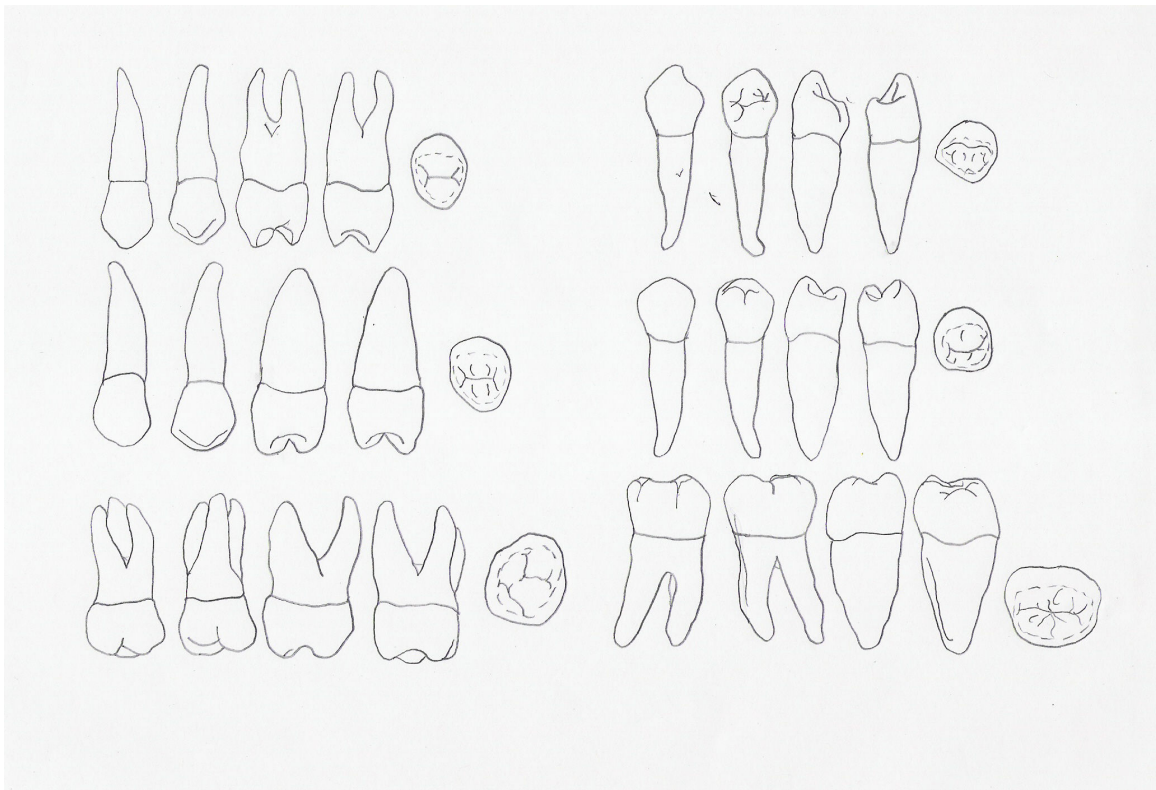
Maxillary Dentition

Top – central incisor. Middle – lateral incisor. Bottom – canine.



Mandibular Dentition

Top – central incisor. Middle – lateral incisor. Bottom – canine.



Top – maxillary premolar 1

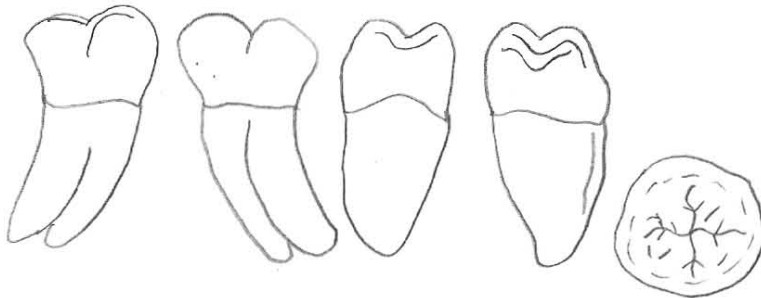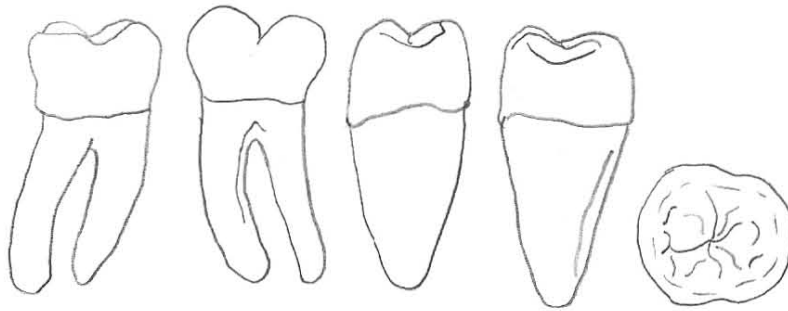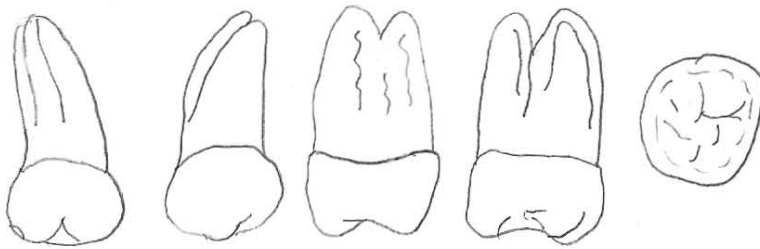
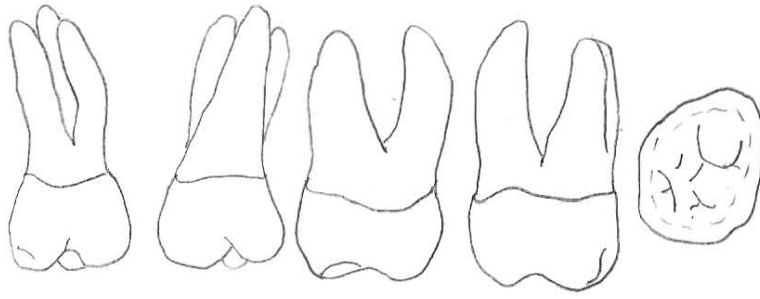
Middle – maxillary premolar 2

Bottom – maxillary molar 1

Top – mandibular premolar 1

Middle – mandibular premolar 2

Bottom – maxillary molar 1



Top – Upper Molars 2 & 3

Bottom – Lower Molars 2 & 3

Dental Variation

Carabelli's cusp – Additional cusp on the mesio-lingual border of the upper molars.

Seen at the highest frequency among those of European descent. (Hillson 1996)

Enamel extension – Found on teeth with multiple roots, enamel extends down the root.

Most commonly found in upper premolars and molars. (Hillson 1996)

Enamel pearl – Found in association with enamel extensions, except the enamel forms a small nodule. Most commonly found in upper second and third molars. (Hillson 1996)

Shovel-shaped incisors – The marginal ridges on the lingual aspect of the incisor are prominent with a deep central fossa. If on the lingual and labial surface this is termed double shoveling.

Supernumerary – Additional teeth, may be seen at multiple locations within the maxillary or mandibular alveoli. These teeth may be peg shaped.

For more information on non-metric dental variation see Hillson's (1996) *Dental Anthropology* or Turner et al. (1991) for an introduction to the series of dental casts of several non-metric traits available through Arizona State University.

Dental Pathology

Abscess – Cavitations in the bone surrounding the tooth root, resulting in the loss of a tooth and eventually absorption of the bone.

Caries – Destruction of one of the three dental structures (enamel, dentine, or cementum), caused by bacteria in the mouth. These may be located on the occlusal surface, smooth surface, within the pulp chamber, at the cemento-enamel junction, or on the root. May be seen as a brown spot in the early phase, followed by creation of a cavity within the affected structure.

Dental enamel hypoplasia – Defect in the enamel of the tooth caused due to developmental issues during secretion of the structure. May cause bands of varying thickness around the circumference of the tooth; also seen in the form of pitting. Thought to be associated with a number of physiological stressors including but not limited to malnutrition, parasites, and weaning.

References

- Aufderheide, A.C. and C. Rodriguez-Martin
1998 *The Cambridge Encyclopedia of Human Paleopathology*. Cambridge University Press, Cambridge.
- Bass, W.M.
1995 *Human Osteology: A Laboratory and Field Manual, 4th Edition*. Missouri Archaeological Society, Inc, Columbia.
- Brothwell, D.R.
1965 *Digging Up Bones*. Cornell University Press, New York.
- Buikstra, J.E. and D.H. Ubelaker
1994 *Standards for Data Collection from Human Skeletal Remains*. Arkansas Archeological Survey Research Series No. 44. Arkansas Archeological Survey, Fayetteville.
- Hillson, S.
1998 *Dental Anthropology*. Cambridge University Press, Cambridge.
- Johnston, F.E.
1962 Growth of the Long Bones of Infants and Young Children at Indian Knoll. *Human Biology* 23:66-81.
- Mann and Hunt
2005 *Photographic Regional Atlas of Bone Disease: A Guide to Pathologic and Normal Variation in the Human Skeleton*. Charles C. Thomas, Springfield.
- McKern, T.W. and T.D. Stewart
1957 Skeletal Age Changes in Young American Males. *U.S. Army Quartermaster Research and Development Command, Technical Report EP-45*.
- Moorrees, C.F.A., E.A. Fanning, and E.E. Hunt, Jr.
1963 Formation and Resorption of Three Deciduous Teeth in Children. *American Journal of Physical Anthropology* 21:205-213.
- Stewart, T.D.
1979 *Essentials of Forensic Anthropology*. Thomas, Springfield.
- Thieme, F.P.
1957 Sex in Negro Skeletons. *Journal of Forensic Medicine* 4:72-81.
- Trotter, M. and G.C. Gleser
1952 Estimation of Stature from Long Bones of American Whites and Negroes. *American Journal of Physical Anthropology* 10:463-514.
1977 Corrigenda to "Estimation of Stature from Long Limb Bones of American Whites and Negroes." *American Journal of Physical Anthropology* 47:355-356.
- Turner, C.G., C.R. Nichol, and G.R. Scott
1991 Scoring Procedures for Key Morphological Traits of the Permanent Dentition: The Arizona State University Dental Anthropology System. In *Advances in Dental Anthropology*, edited by M.A. Kelley and C.S. Larsen, pp. 13-31. Wiley-Liss, Inc, New York.
- White, T.D.
2000 *Human Osteology*. Academic Press, San Diego.